
Increased Volume and Glial Density in Primate Prefrontal Cortex Associated with Chronic Antipsychotic Drug Exposure

Lynn D. Selemon, Michael S. Lidow, and Patricia S. Goldman-Rakic

Background: Long term medication with antipsychotic drugs is known to produce changes in neurotransmitter levels and receptor sensitivity in the cortex; however, the anatomic consequences of chronic antipsychotic exposure are not well established.

Methods: Accordingly, rhesus monkeys were given daily oral doses of typical or atypical antipsychotic drugs (TAP or AAP) or a placebo for 6 months. After treatment, a stereologic method was used to assess neuronal and glial density and cortical thickness in prefrontal area 46.

Results: Neuronal density in drug-treated monkeys and controls did not differ in any cortical layer. Glial density was elevated in monkeys that received antipsychotic medications: as much as 33% in layers that receive dense excitatory afferents (layers I in TAP monkeys and IV in AAP monkeys). In addition, layer V was wider in all drug-treated monkeys.

Conclusions: Our findings indicate that glial proliferation and hypertrophy of the cerebral cortex is a common response to antipsychotic drugs. We hypothesize that these responses play a regulatory role in adjusting neurotransmitter levels or metabolic processes. Finally, the negative results with respect to neuronal density indicate that the elevated neuronal density found in the schizophrenic cortex is unlikely to be a medication effect. *Biol Psychiatry* 1999;46:161-172
© 1999 Society of Biological Psychiatry

Key Words: Glia, dopamine, frontal cortex, schizophrenia, bipolar disorder, animal

Introduction

Since the 1950s, antipsychotic drugs, that act primarily by blocking D₂ receptors, have been widely prescribed to ameliorate the psychotic symptoms of schizophrenia.

More recently, atypical antipsychotics, as exemplified by clozapine, have broadened the spectrum of antipsychotic medication in the treatment of schizophrenia. Atypical drugs produce fewer extrapyramidal side effects and in some instances have greater efficacy in alleviating positive, negative or cognitive symptoms of the disease (Kinon and Lieberman 1996). Whereas the effects of antipsychotic drugs on receptor binding and transmitter turnover have been intensively studied in animal models and humans (Deutch et al 1991; Farde et al 1992; Lidow and Goldman-Rakic 1994; 1997; Lidow et al 1997; Meltzer et al 1994; Roth et al 1994; Kinon and Lieberman 1996), little is known about the impact of antipsychotic drug treatment on brain morphology. The few available studies indicate that drug treatment can produce structural changes of considerable magnitude. For example, neuroimaging studies have shown that chronic treatment with haloperidol, a typical antipsychotic drug, induces marked enlargement of the caudate nucleus (Chakos et al 1994; Keshavan et al 1994; Gur et al 1998). The underlying anatomical mechanism for this enlargement has not been determined. Alterations in the size, transmitter content and post-synaptic targets of inhibitory synaptic terminals have been observed after chronic exposure to antipsychotic drugs (Benes et al 1985a,b; Vincent et al 1991, 1994). Such findings indicate that a dynamic relationship exists between changes in transmitter-receptor interactions and the structure of neural elements in the brain.

Determining the exact anatomic basis of antipsychotic effects in the brain is important not only for a better understanding of drug action but also to evaluate anatomical findings in brains from schizophrenic patients who have undergone antipsychotic therapy. We have previously reported increased neuronal density in conjunction with slight cortical thinning in the dorsolateral prefrontal cortex of schizophrenic patients in comparison to the normal control cortex (Selemon et al 1995, 1998). Moreover, somal size of layer IIIc neurons is reduced in this same area (Rajkowska et al 1998). Because most of the schizophrenic subjects in these studies, as in most other postmortem studies, are treated with antipsychotic drugs,

From the Section of Neurobiology, Yale University School of Medicine, New Haven, Connecticut (LDS, PSG-R); and Department of Oral and Craniofacial Biological Sciences and Program in Neuroscience, University of Maryland, Baltimore, Maryland (MSL).

Address reprint requests to Dr. Lynn Selemon, Section of Neurobiology, Yale University School of Medicine, 333 Cedar St., Rm. C-303 SHM, New Haven, CT 06510.

Received March 3, 1999; revised April 20, 1999; accepted April 27, 1999.

the morphometric abnormalities observed in postmortem studies could be due to the effects of medication rather than associated with the disease process.

In the present study, we have examined the effects of chronic treatment over a six month period with six different typical and atypical antipsychotic drugs on the anatomy of the prefrontal cortex in rhesus monkeys with the same 3-D counting method that was employed in our postmortem studies of schizophrenic brains, a method that yields quantitative information on neuronal density, glial density and cortical thickness. No evidence was found for the increased neuronal density nor the reduction of cortical thickness that characterizes the schizophrenic brain. Rather, chronic antipsychotic exposure was associated with laminar-specific gliosis and hypertrophy of layer V in the prefrontal cortex of drug-treated monkeys. These results underscore the potential beneficial role for gliosis as a homeostatic response to changes in neuronal activity and further suggest that analogous glial proliferation or hypertrophy in the caudate nucleus may account for the volumetric changes observed in schizophrenic patients undergoing antipsychotic therapy. A preliminary report of these findings was presented at the VIth International Congress on Schizophrenia Research (Selemon et al 1997).

Methods and Materials

Six antipsychotic drugs were selected to represent a spectrum of major chemical classes of drugs currently used in clinical practice and including both typical (chlorpromazine, haloperidol, pimozide) and atypical (clozapine, olanzapine, risperidone) classifications. Seventeen male rhesus monkeys, 3–5 years of age, were administered daily doses of antipsychotic drugs or placebo for 6 months. The drugs were given orally (in fruit treats) twice a day to replicate clinical maintenance regimens for human subjects (Hyman and Arana 1987). The drug dosages matched those commonly used in human patients (see Table 1; Lidow et al 1997). Five monkeys who received fruit treats only constituted the placebo-treated control group (PC); 12 monkeys received 1 of 6 antipsychotic drugs (chlorpromazine [$n = 2$]; haloperidol [$n = 2$]; pimozide [$n = 2$]; clozapine [$n = 2$]; olanzapine [$n = 2$]; and risperidone [$n = 2$]). Based on previous biochemical analyses in these same monkeys that indicated that all six drugs under the treatment regimens used in this study have the common effect of up regulating the D_2 receptor (Lidow and Goldman-Rakic 1994, 1997; Lidow et al 1998), we elected to pool all drug-treated monkeys in the initial analysis for comparison to the PC group. Secondly, the antipsychotic treated monkeys were divided according to clinical classification of the drugs into a typical antipsychotic group (TAP Group: chlorpromazine, haloperidol, pimozide) and an atypical antipsychotic group (AAP Group: clozapine, olanzapine, risperidone).

At 12–18 hours after completion of the drug treatment period, the monkeys were anesthetized with sodium pentobarbital and perfused intracardially with phosphate-buffered saline for 2 minutes to clear blood from the tissue. The brains were removed,

and a small block of the cortex surrounding the principal sulcus (area 46) was dissected and placed in 10% formalin for 1–5.5 months. The blocks were subsequently embedded in celloidin and cut on a sliding microtome to generate 40 μ m thick sections. The sections were Nissl-stained to reveal the somata of neurons and glia. All slides were coded before analysis so that the investigator (LDS) was blind to drug treatment protocol during cell counting.

Neuronal and glial density, as well as cortical thickness, were assessed in area 46 using the direct, 3-dimensional counting method (Williams and Rakic 1988) described in detail in Selemon et al. (1985) and briefly outlined here. In each monkey brain, cells were counted in five probes consisting of contiguous counting boxes (35 μ m \times 55 μ m) and stretching from the pial surface to the white matter below layer VI; thus, five independent 35 μ m-wide columns of cortex were counted in each brain. The 5 probes were located in the middle of the dorsal bank of the principal sulcus in 5 different sections that were evenly spaced throughout the block containing area 46. Neurons and glia were counted separately. Glia were distinguished from neurons on the basis of their smaller size, the absence of visible cytoplasm, a darker nuclear membrane, and the presence of a dispersed pattern of nuclear chromatin (Figure 1). Neuronal and glial density from the 5 probes were averaged to compute a mean density for each monkey brain. All brain means in the PC and drug-treated monkeys were averaged to obtain group means for the initial analysis; likewise, individual brain means for each of the 3 treatment groups (PC, TAP, AAP) were averaged to obtain a mean value for the group.

A single factor analysis of variance (ANOVA) was used to test for significant effects of drug treatment on the 3 dependent variables: neuronal density, glial density and cortical thickness. Layer-specific differences were analyzed using a single factor repeated measures ANOVA with layers as the repeated measures. In the initial analysis, post-hoc analysis of drug-treated monkeys in comparison to the control group (PC) was performed. Secondary analysis of typical and atypical groups (TAP and AAP) with PC group were performed; to compensate for multiple comparisons, a Bonferroni corrected p value of $p < .025$ was selected as the criterion for significance. In addition, multivariate regression analysis was employed to assess the influence of age and time in formalin (TF) on these same 3 variables.

Results

Qualitative Observations

Nissl-stained sections of the cortex surrounding the principal sulcus exhibited a cytoarchitectonic composition consistent with that previously described for area 46 (Walker 1940). Specifically, supragranular layers were thicker than infragranular layers with a well-defined layer IV separating them. The cytoarchitectonic structure of area 46 in the drug treated monkeys did not differ from that of controls (Figure 2) with the exception of one brain from a monkey treated with risperidone that exhibited pathology of the hypoxic, ischemic

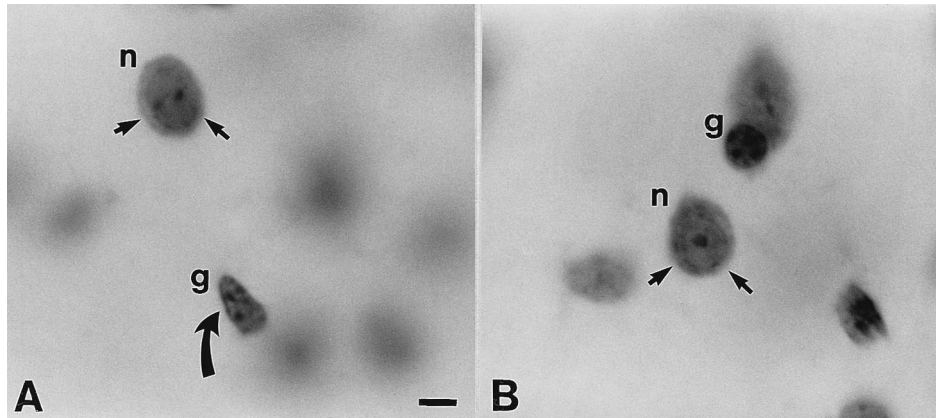


Figure 1. High power photomicrographs illustrating the morphologic distinction between small neurons and glia. (A) Neurons (n) have a visible rim of cytoplasm surrounding the nucleus (small arrows) and a prominent nucleolus. In contrast, glia (g) do not have a cytoplasmic rim, have a more dispersed chromatin pattern in the nucleus, and have a darker nuclear membrane (curved arrow). (B) Another example of a small neuron (n) with visible cytoplasm (small arrows) and prominent nucleolus is shown next to a glial cell. Scale bar = 10 μm .

type (Figure 3). In this animal, there were multiple, small areas in the principal sulcal cortex that were devoid of neurons and filled with glial cells. These territories tended to be elongated along the axis perpendicular to the pial surface, often were associated with radial blood vessels, and did not seem to be located preferentially in any layer. In fact, the areas devoid of neurons often encompassed more than one layer and in the depth of the sulcus seem to extend throughout the entire thickness of the cortex. Most of these gliotic scars were located within the principal sulcal cortex. A few were located in the prefrontal cortex immediately dorsal and ventral to the principal sulcus. Because only a small block of prefrontal cortex was available for anatomical study from this monkey, it cannot be determined whether similar pathological changes occurred elsewhere in the brain. It should be noted that the probes for cell counting in the risperidone monkey with marked cortical pathology were located in portions of cortex that were free from pathology.

Quantitative Measurements

GLIAL DENSITY. Mean glial density across all layers for the PC monkeys was 91.58 ± 9.33 (SD) glia/ $(.001 \text{ mm}^3 \times 10^{-3})$ and was slightly, but not significantly higher in the pooled group of drug treated monkeys (103.31 ± 15.04 glia/ $[.001 \text{ mm}^3 \times 10^{-3}]$; $F = 2.57$; $p = .13$). Laminar analysis revealed higher glial densities in the drug treated group in layers I–V ranging from 10–28%; only the elevation in layer IV (28%) reached the level of statistical significance ($F = 6.333$; $p = .024$). Glial density in layer VI was nearly identical in drug-

treated and control monkeys. Separate analysis of TAP and AAP groups revealed a similar pattern. Overall glial density in the TAP-treated (103.91 ± 15.52 glia/ $[.001 \text{ mm}^3 \times 10^{-3}]$; $F = 1.957$; $p = .185$) and AAP-treated groups (102.72 ± 16.01 glia/ $[.001 \text{ mm}^3 \times 10^{-3}]$; $F = 1.673$; $p = .217$) slightly but not significantly higher than that of the PC group (Figure 4). On a layer by layer basis, the magnitude of elevation varied from 16–31% in layers I–V in the TAP-treated monkeys; in the AAP group glial density was higher in layer I (11%) and III–V (8.5%–33%) (Figure 5). There were no significant drug by layer interactions in either the pooled drug treated group or in the TAP or AAP groups in comparison to PC monkeys. Post-hoc comparison of glial density in specific layers revealed a significant increase in glial density in layer I in the TAP-treated monkeys ($F = 6.698$; $p = .023$) and in layer IV of the AAP-treated monkeys ($F = 6.405$; $p = .024$) relative to the PC monkeys, corresponding to the layers having the greatest percentage increase in glial density (31% and 33%, respectively). Analysis of glial density across all layers for individual drugs showed only trend elevations for chlorpromazine, pimozide, and olanzapine whereas the other 3 drugs, haloperidol, clozapine and risperidone exhibited glial densities comparable to controls (Table 1).

NEURONAL DENSITY. Overall neuronal density in the PC monkeys (132.97 ± 10.65 neurons/ $[.001 \text{ mm}^3 \times 10^{-3}]$) and drug-treated monkeys (133.21 ± 14.97 neurons/ $[.001 \text{ mm}^3 \times 10^{-3}]$; $F = .001$; $p = .974$) was nearly identical. Moreover, no significant differences between drug-treated and control monkeys were re-

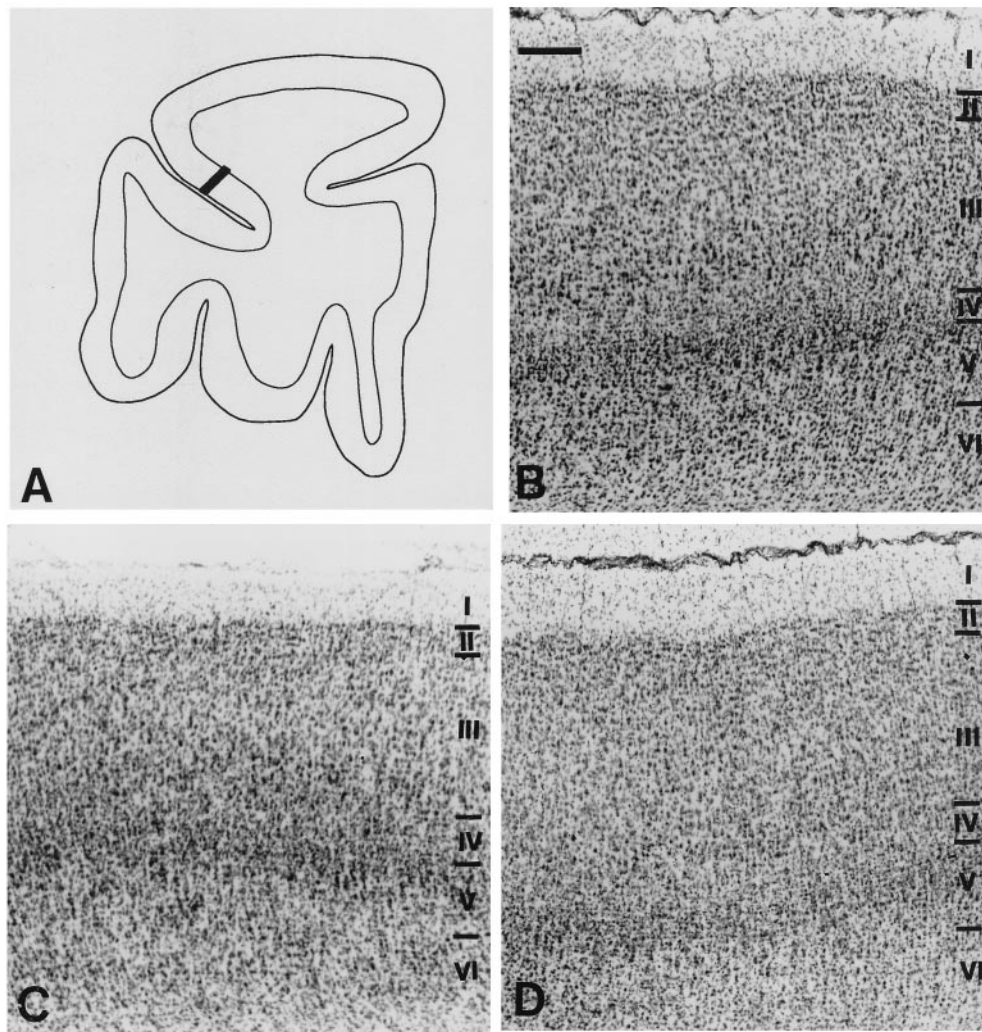


Figure 2. Cytoarchitectonic structure of (A) the dorsal bank of the principal sulcus (Walker's area 46) in (B) a control monkey and in monkeys treated with (C) haloperidol and (D) clozapine, respectively. No overt abnormalities were observed in monkeys treated with typical or atypical antipsychotic drugs with the exception of risperidone (see Figure 3). Scale bar = 200 μ m.

vealed with layer by layer analysis. TAP and AAP-treated groups had mean neuronal density values of 138.69 ± 12.72 neurons/[$.001 \text{ mm}^3 \times 10^{-3}$] ($F = 0.755$; $p = .401$) and 127.73 ± 16.10 neurons/[$.001 \text{ mm}^3 \times 10^{-3}$] ($F = 0.409$; $p = .533$) respectively, that were also not different from that of the PC group (Figure 4). Lamiar analysis of TAP-treated monkeys in comparison with PC did not uncover any significant differences (Figure 6). In AAP-treated monkeys, only layer II showed a significant decrease in neuronal density in comparison to PC ($F = 6.993$; $p = .019$). This difference was clearly attributable to the effects of one drug, risperidone (Table 1), as revealed by separate laminar analyses in risperidone- and clozapine/olanza-

pine-treated monkeys, respectively (Figure 6). No significant drug by layer interactions were observed.

CORTICAL THICKNESS AND PERCENT LAMINAR WIDTH. Mean total cortical thickness in area 46 in PC monkeys was 1.38 ± 0.13 mm and slightly but not significantly greater in drug-treated monkeys (1.44 ± 0.064 mm; $F = 1.673$; $p = .215$). The relative contribution of each layer to cortical thickness in PC and drug-treated groups was also similar for all layers except layer V that was proportionately thicker in drug-treated monkeys ($F = 5.873$, $p = .028$). Total cortical thickness in TAP-treated (1.45 ± 0.08 mm; $F = 1.190$; $p = .295$) and AAP-treated monkeys (1.44 ± 0.04 mm; $F = 1.140$; $p = .304$) was

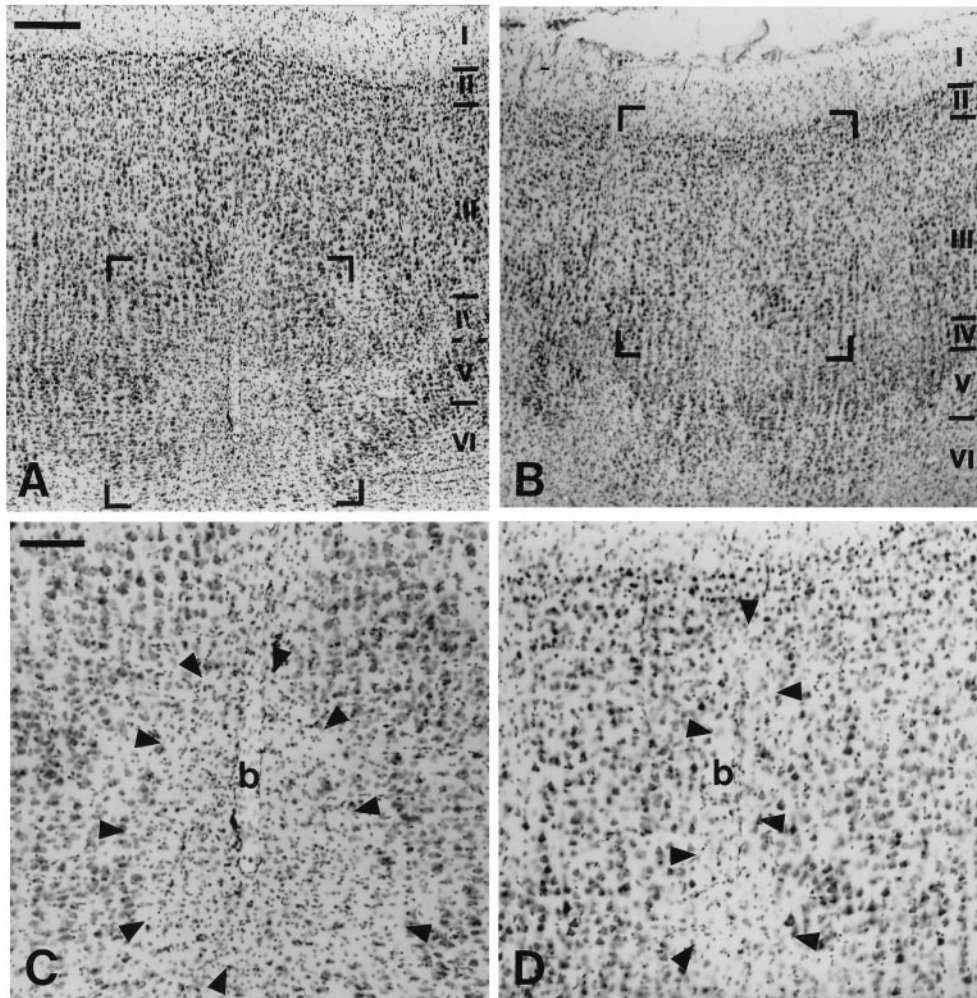


Figure 3. Photomicrographs illustrating multiple focal areas of neuronal degeneration in a monkey after daily risperidone administration for 6 months. Low power magnification of the (A) dorsal and (B) ventral principal sulcal cortex in the risperidone-treated monkey. (C) (D) Higher power views showing the areas bracketed in (A) and (B) in which glial areas devoid of neurons (arrowheads) are clustered around a central blood vessel (b). (A), (B) scale bar = 200 μm ; (C), (D) scale bar = 100 μm .

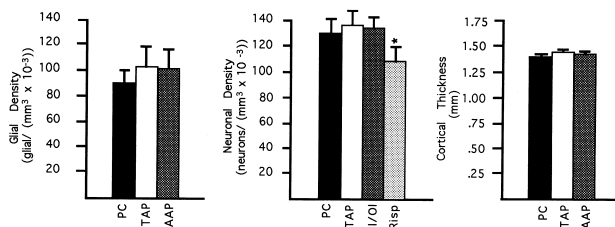


Figure 4. Graphs illustrating overall glial density, neuronal density and cortical thickness in monkeys treated with typical antipsychotics (TAP) or atypical antipsychotics (AAP) in comparison to placebo controls (PC). Note that mean neuronal density for the risperidone treated monkeys (Risp) is shown separately from that of monkeys receiving the other two atypical antipsychotic drugs, clozapine and olanzapine (Cl/Ol) to illustrate the neurodegenerative effects of risperidone.

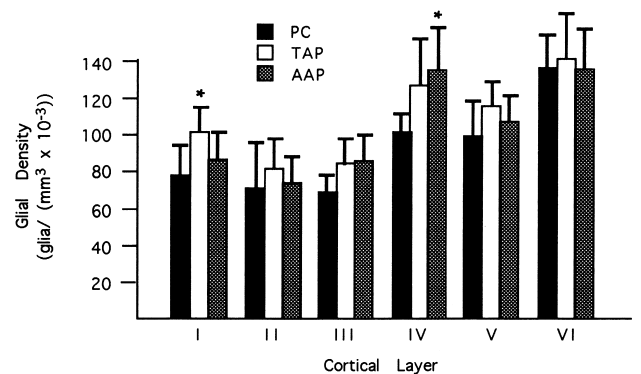


Figure 5. Laminar glial density in area 46 in placebo-treated control (PC), monkeys receiving chronic administration of typical antipsychotic (TAP) or atypical antipsychotic drugs (AAP). Glial density was significantly elevated in layer I in monkeys treated with TAP and in layer IV in AAP treated monkeys. Trend elevations were present in layer II, III and V as well.

Table 1. Glial and Neuronal Density for Individual Drugs

Daily drug dosage	Glial density	Neuronal density
Placebo control	91.58 ± 9.33	132.97 ± 10.65
Haloperidol 0.20 mg/kg	92.70 ± 10.32 <i>p</i> = .929	137.16 ± 8.64 <i>p</i> = .691
Chlorpromazine 2.80 mg/kg	108.14 ± 9.47 <i>p</i> = .205	139.47 ± 19.25 <i>p</i> = .539
Pimozide 0.20 mg/kg	110.89 ± 22.44 <i>p</i> = .145	139.45 ± 15.73 <i>p</i> = .540
Clozapine 5.20 mg/kg	97.59 ± 0.06 <i>p</i> = .633	133.82 ± 10.15 <i>p</i> = .935
Olanzapine 0.35 mg/kg	113.01 ± 24.32 <i>p</i> = .110	140.07 ± 1.08 <i>p</i> = .503
Risperidone 0.20 mg/kg	97.57 ± 19.30 <i>p</i> = .635	109.31 ± 11.57 <i>p</i> = .043

Table 2. Percent Laminar Width

Cortical layer	PC	TAP	AAP
I	12.68 ± 1.91	11.40 ± 1.00 <i>p</i> = .112	12.70 ± 0.68 <i>p</i> = .979
II	7.72 ± 1.40	7.63 ± 1.31 <i>p</i> = .912	7.27 ± 1.12 <i>p</i> = .566
III	36.70 ± 3.92	34.40 ± 2.32 <i>p</i> = .239	37.53 ± 2.70 <i>p</i> = .652
IV	9.51 ± 2.08	9.63 ± 0.45 <i>p</i> = .885	9.33 ± 1.26 <i>p</i> = .838
V	10.75 ± 1.39	14.20 ± 1.99 <i>p</i> = .006	12.20 ± 1.72 <i>p</i> = 1.89
VI	22.52 ± 5.06	22.97 ± 2.27 <i>p</i> = .832	20.83 ± 2.44 <i>p</i> = .419

comparable to the mean of the pooled drug treated group and not significantly different from the PC group (Figure 4). Layer V was proportionately larger only in the TAP-treated groups relative to the PC group ($F = 10.942$; $p = .006$) (Table 2). Absolute laminar width of layer V was also significantly greater in drug treated monkeys (0.193 ± 0.009 mm; $F = 7.661$; $p = .014$), as well as the TAP subgroup (0.205 ± 0.012 mm; $F = 9.593$, $p = .008$), in comparison to controls (0.146 ± 0.014 mm).

Regression Analysis

There was no effect of age or TF on neuronal ($r^2 = 0.251$ $p = .074$, age; $p = 0.101$, TF) or glial density ($r^2 = .095$; $p = .265$, age; $p = .545$, TF), nor was there a correlation between age or TF and cortical thickness ($r^2 = 0.086$; $p = 0.295$, age; $p = .623$, TF).

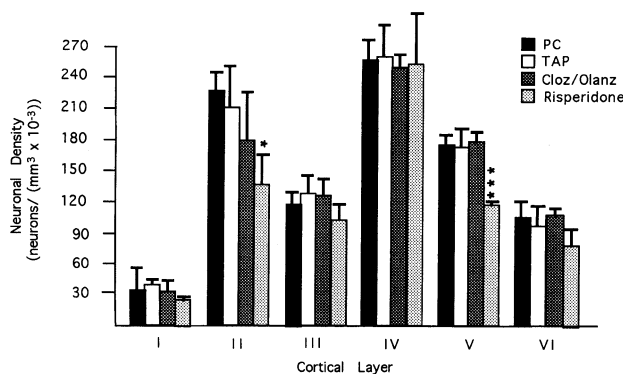


Figure 6. Overall neuronal density for each of the six cortical layers is shown for placebo controls (PC), monkeys treated with typical antipsychotics (TAP), and monkeys treated with either clozapine or olanzapine (Cloz/Olanz) or risperidone. Only the risperidone treated monkey exhibited significant reductions in neuronal density in layers II and V.

Discussion

Glial Proliferation in Response to Antipsychotic Treatment

Glial density was elevated in the drug-treated monkeys relative to the placebo control group. The most pronounced and only significant elevation was found in layer IV although glial density was also higher in all other layers with the exception of layer VI. This laminar specific increase in density probably represents the addition of new glial cells as there was no indication of cortical volume loss in these animals. In fact, cortical thickness tended to be slightly greater in the drug treated animals relative to controls due to enlargement of layer V. The morphometric profile observed after antipsychotic administration contrasts with that observed in the schizophrenic cortex where glial density is elevated in parallel with an increase in neuronal density. These experimental findings thus suggest that the greater cell packing of both neurons and glial found in the schizophrenic cortex is not a medication effect. The selective increase in glial density in conjunction with expansion of the cortical ribbon in drug-treated animals is consistent with proliferation of glial cells after chronic antipsychotic exposure.

Although it is generally agreed that frank gliosis is not a pathologic feature of the schizophrenic cortex (e.g., Benes et al 1991), one recent preliminary report indicates that there may be increased microglial density in prefrontal area 9 in postmortem brains from schizophrenic patients (Radewicz et al 1997). As microglial cells are thought to proliferate in response to the presence of foreign substances in the brain, the increase in glial density observed in the present study may represent this form of mild inflammatory reaction to the drugs. In addition, classic gliotic reactions involving hypertrophy and proliferation of astroglial cells have been observed to a variable degree in subcortical structures in schizophrenic brains (Stevens 1982; Bruton et al 1990). The present study raises the possibility that some of the evidence for gliosis in

schizophrenia and the variability in glial cell density from case to case may be due to exposure to antipsychotic treatment. Moreover, it is possible that long term antipsychotic intake contributes to the marked gliosis reported in a subpopulation of elderly, demented schizophrenic patients (Arnold et al 1996). In the present analysis, we did not attempt to discriminate the various morphologic and functional subtypes of glial cells; further studies using immunocytochemical methods are needed to determine the contribution of astroglial and microglial subtypes to the increase in glial density.

It is interesting that the specific laminae, layers I and IV, exhibiting the most pronounced increases in glial density after exposure to typical and atypical antipsychotic drugs, respectively, also represent the layers receiving the densest terminal innervation from cortico-cortical projections (Goldman and Nauta 1977; Selemon and Goldman-Rakic 1988). This association may suggest that the glutamatergic cortico-cortical connections that mediate higher cognitive functioning are prominent targets of antipsychotic drug action. Glia are known to resorb glutamate (Pellerin and Magistretti 1994; Rothstein et al 1994), and therefore the increase in glial density may be linked to increased glutamatergic transmission after antipsychotic drug intake (Gattaz et al 1982; Kim et al 1983; Lidsky et al 1997).

Cortical Site and Action of Antipsychotic Drugs

The therapeutic action of antipsychotic drugs has been correlated with occupancy at the dopamine D₂ receptor although these drugs interact with other receptors including prominently D₁, serotonin and muscarinic sites (Seeman et al 1976, 1990). Autoradiographic localization of D₂ binding sites in cortex suggests a predominant distribution of the D₂ receptor in layer V in the nonhuman primate (Goldman-Rakic et al 1990) and infragranular layers V and VI in the rat (Vincent et al 1993). Furthermore, several lines of evidence suggest that dopamine receptors are located on glial cells. For example, adenylate cyclase coupled dopamine receptor sites (D₁ receptors) have been localized on glial membranes (Henn et al 1977; Eriksson et al 1991). More recently, immuno-electron microscopic evidence has revealed D₂S (short) and D₂L (long) dopamine receptors located on glia as well as on neurons in the cortex. Further, the two D₂ isoforms are located on glial cells that encapsulate nonpyramidal neurons (Khan, Ladislav, and Goldman-Rakic, personal communication). Importantly, dopamine has been shown to regulate cell number in a variety of proliferating cell populations usually via promotion of proliferation at D₂ receptors and inhibition at D₁ receptors (Schrell et al 1990; Lajiness et al 1993; Yamaguchi et al 1996; Yasunari et al

1997; Zhang and Cincotta 1997; Saiardi et al 1997) although in some systems stimulation of D₂ receptors inhibits cell proliferation (Arita et al 1998). Thus, recent findings suggest that dopamine may play a direct role in regulating glial cell number via dopamine receptors on glia although there are compelling arguments for indirect actions as well (see below). In the present study, increased glial density in layer IV and increased laminar width in layer V was found in the pooled group of all drug-treated monkeys. Although glial cell density was not significantly increased in layer V, the enlargement of this lamina may be due to a modest increase in the number of glial cells and addition of glial processes. Whereas it is not clear how antipsychotics stimulate glial proliferation in cortex, the long-term exposure to antipsychotic drugs may be a critical factor. In the same monkeys utilized for stereologic cell counting in the present study, all six antipsychotic drugs upregulated the amount of D₂ message in the prefrontal and temporal cortices (Lidow and Goldman-Rakic 1997; Lidow et al 1997). This increase in D₂ mRNA levels is consistent with the induction of glial proliferation observed in this study.

Mild Gliosis: Possible Response to Increased Glutamate Turnover

Although much attention has focused on dopaminergic systems in schizophrenia because the discovery of antipsychotic drugs in the 1950s, more recently it has been proposed that disruption of glutamatergic transmission may be a critical feature of the schizophrenic pathology (Kim et al 1980; Deutsch et al 1989; Olney and Farber 1995; Tamminga 1998). Mounting evidence suggests that the antipsychotic action of drugs may be mediated by increasing glutamatergic activity (Gattaz et al 1982; Kim et al 1983; Lidsky et al 1997). In the cortex, antipsychotic drugs probably exert this influence via indirect antagonistic actions at dopamine receptors or through more direct actions on serotonin (5-HT₂) receptors that are located on the spines and proximal shafts of pyramidal apical dendrites, respectively (Goldman-Rakic 1987; Goldman-Rakic et al 1992; Bergson et al 1995; Jakab and Goldman-Rakic 1998). Taken together with recent evidence that astrocytes possess receptors and reuptake sites for neurotransmitters including glutamate (Pellerin and Magistretti 1994; Rothstein et al 1994), these findings raise the possibility that enhanced glutamate transmission in the cortex has an impact on glial cell morphology or number. Although the mechanism for glial induction after enhancement of glutamatergic neurotransmission is purely speculative at this point, it seems reasonable that an increased demand for uptake of glutamate could signal the need for proliferation of glial processes and perhaps the addition of

new glial cells. Astroglial cells, that not only make intimate contact with neuronal processes but also with capillary walls, are thought to play a role in coupling of neuronal activity and metabolic energy consumption, as well as increasing synaptic efficacy (Magistretti and Pelletier 1997; Pfeiffer and Barres 1997). There is, in addition, a complex interaction between dopamine and the cortical microvasculature: dopaminergic axons form appositions with glial cells blood vessel walls of the capillaries (Kramer et al 1998). Thus, antipsychotics may indirectly affect glial activity and perhaps number by increasing neurotransmission or via effects on cortical blood perfusion.

Antipsychotic Effects Do Not Account for the Morphometric Abnormalities Found in Schizophrenic Patients

Neuronal density in the prefrontal cortex of monkeys that had undergone antipsychotic exposure of six months duration was not different from neuronal density of placebo-treated monkeys. This finding contrasts with that of previous morphometric analyses using the same stereologic cell counting methodology to assess neuronal density in the prefrontal cortex of schizophrenic patients. In prefrontal areas 9 and 46 in human schizophrenic brains, neuronal density was elevated by 18% and 21%, respectively (Selemon et al 1995, 1998). Moreover, although there was a regionally specific laminar pattern of neuronal elevation in these 2 areas with area 9 showing increased neuronal density in layers III–VI and significant elevations in layers II, III, IV, and VI in area 46, trend elevations were observed in all layers. In monkeys treated with either typical or atypical antipsychotic drugs, there was no tendency for neuronal density to be higher overall or in any specific layers. As schizophrenic patients are often treated with antipsychotic medications for many years, these experiments cannot duplicate the long-term exposure of a human subject. Nevertheless, the fact that there was no tendency toward elevation in neuronal density in the prefrontal cortex suggests that the increase in cell packing density observed in schizophrenic brains is not a medication effect. Moreover, changes in cortical thickness in drug treated monkeys were opposite in direction from those observed in schizophrenic patients. After antipsychotic treatment in monkeys, the prefrontal cortex tended to be thicker than that of controls whereas cortical thickness was reduced by approximately 8% in schizophrenic brains (Selemon et al 1995, 1998). Furthermore, after chronic treatment with typical antipsychotic drugs, the proportionate thickness of layer V was increased whereas the exact opposite result, i.e., decrease in thickness of this layer, was observed in schizophrenic brains (Selemon et al 1995).

Indeed, in view of the present findings of glial prolifer-

ation and cortical thickening in response to antipsychotic medication, it is possible that morphometric disturbances in schizophrenic brains may be partially masked or confounded by antipsychotic exposure. We might have observed a larger decrease in layer V thickness if a cohort of neuroleptic naive brains had been examined. Likewise, this study suggests antipsychotic exposure may influence volumetric measurements in MRI studies and that greater deficits might be expected in neuroleptic naive subjects in comparison to medicated patients at the same stage of illness. One recent MRI study found that the reduction in volume of the superior temporal gyrus (STG) observed in first episode, neuroleptic-naive schizophrenic patients reversed at one year follow-up (Keshavan et al, 1998a). The increase in STG volume following initiation of treatment could be due to glial proliferation in response to antipsychotic medication of these patients. In our previous post-mortem study of neuronal and glial density changes associated with schizophrenia (Selemon et al 1995), we observed a trend elevation in glial density in schizophrenic brains that was greater in magnitude but more variable than the increase in neuronal density. The present results suggest that medication effects may account for the variability in glial density in postmortem brains and in part for the disputed presence of a gliotic reaction in schizophrenic brains (Stevens 1982; Bruton et al 1990; Benes et al 1991).

One well documented side effect of typical antipsychotic drugs in schizophrenic patients is increased volume of the caudate nucleus on MRI scan (Chakos et al 1994; Keshavan et al 1994; Gur et al 1998), an effect that is apparently medication dependent because antipsychotic naive subjects have smaller than normal caudate volumes (Keshavan et al 1998b). We might speculate that glial proliferation is the underlying process for enlargement of the caudate nucleus in schizophrenic patients medicated with typical antipsychotics. It is known that typical antipsychotic drugs act on both nigrostriatal and tegmental cortical dopamine projections whereas atypical antipsychotics are more specific for the cortical system (Kinon and Lieberman 1996). Therefore, the typical antipsychotic haloperidol may cause an increase in glial proliferation in the caudate that is analogous to the effects observed in the present study in the cortex. Other lines of evidence suggest that chronic antipsychotic treatment may mediate sprouting or elaboration of neuronal processes in the neostriatum via enlargement of dendritic and axonal diameters (Benes et al 1985b) or via increases in glutamate-containing perforated synapses (Meshul et al 1994), overall number of synaptic boutons in the neostriatum (Kerns et al 1992) and in met-enkephalin immunoreactive processes in the globus pallidus (Auchus and Pickel 1992). One recent report suggests that dendritic spine density is reduced in

the neostriatum after chronic haloperidol treatment (Kelley et al 1997) suggesting that antipsychotic effects on neuronal neuropil are complex and may not necessarily contribute to caudate enlargement. In the cortex, only subtle changes in transmitter content and synaptic rearrangement have been reported after chronic haloperidol treatment (Benes et al 1985a; Vincent et al 1991, 1994). The present results in which neuronal density was unaltered by long term treatment with antipsychotics is consistent with the absence of conspicuous changes in cortical neuronal morphology.

Risperidone Toxicity: Related to Vascular Ischemia?

Risperidone treatment in monkeys administered at concentrations comparable to therapeutic doses for human subjects resulted in marked pathological changes in the prefrontal cortex in one monkey and a quantitatively documented neuronal loss in the second animal. It must be kept in mind, however, that drug metabolism differs markedly in the human and non-human primate (Stafford et al 1981; Lidow and Goldman-Rakic, unpublished observations) and that blood concentrations of the drug and receptor occupancy were not determined. Therefore, it is quite possible that the risperidone dosage utilized in this study inadvertently represented a toxic level of the drug. In the monkey with overt pathology, there were numerous areas devoid of neurons in principal sulcal cortex and to a lesser degree in the surrounding cortex. The proximity of these neuron-free patches to radial blood vessels, as well as their elongated shape, suggest that the loss of neurons is related to hypoxic ischemic events, possibly related to dopamine regulation of the microcirculation (Krimer et al 1998). Neuronal density in both animals was greatly reduced from the control mean, perhaps indicating that more subtle neuronal loss occurs outside of these patchy areas. Risperidone is now widely used in the treatment of schizophrenia with excellent success in improving psychotic symptoms and quality of life for these patients (Chouinard et al 1993; Lindstrom and von Knorring 1994; Marder and Meibach 1994; Kopala et al 1996). Indeed, risperidone has even been reported to be superior to other antipsychotic drugs in improving verbal working memory deficits (Green et al 1997). The only known negative side effect of risperidone in human patients is the emergence of obsessive-compulsive symptoms in a small percentage of patients. In two reports, patients previously suffering from obsessive-compulsive disorder relapsed after treatment with risperidone (Kopala and Honer 1994; Remington and Adams 1994), but in a more recent study symptoms of the disease appeared in a paranoid schizophrenic patient who had no prior history of obsessive-compulsive disease

(Alzaid and Jones 1997). Obsessive-compulsive disorder has been successfully treated with pharmacologic agents that potentiate 5-HT transmission (Eddy and Walbroehl 1998; Seksel and Lindman 1998), and therefore the emergence of obsessive-compulsive symptomatology after risperidone administration could be due to the drug's potent 5-HT₂ receptor blocking properties. Indeed, risperidone has a high affinity for 5-HT₂ receptors in the frontal cortex (Matsubara et al 1993; Sumiyoshi et al 1994) although not necessarily higher than that of other antipsychotic medications and therefore it is unclear why obsessive-compulsive disorder is preferentially associated with risperidone treatment. Interestingly, two recent reports suggest that obsessive-compulsive disorder is sometimes found in association with cortical lesions involving frontal, temporal, or cingulate areas (Swoboda and Jenike 1995; Berthier et al 1996); thus, it is possible that ischemic related neuronal death in selectively vulnerable cortical areas contributes to the mechanism for risperidone toxicity in obsessive-compulsive disorder.

A New Perspective on Glial Pathology and Psychiatric Illness

Gliosis, involving both glial proliferation and hypertrophy, is a hallmark of many forms of neuropathology associated with neuronal degeneration whether due to injury or disease. Neuropathological studies of psychiatric illnesses, as for example schizophrenia, find little or no evidence of gliosis (Benes et al 1991; Selemon et al 1995, 1998; Rajkowska et al 1998). Indeed, recent postmortem analyses of brains from patients with major depression or bipolar disorder revealed abnormally low glial density and/or numbers in the frontal cortex (Rajkowska et al 1997; Drevets et al 1998; Ongur et al 1998). These studies raise the possibility that deficient numbers of cortical glia are associated with abnormal functional capacity of the cortex, although whether a decrease in glial number is the primary pathological deficit or, instead, glia cells decline in response to aberrant neuronal activity is not presently clear. As glia are now thought to play an essential role in regulating metabolic activity and blood flow in the cortex (Magistretti and Pellerin 1997; Krimer et al 1998), a deficit in glia number could have pathologic consequences for neuronal activity and function. Conversely, proliferation of glia in response to antipsychotic treatment, for example, may be beneficial to cortical function despite the negative connotation of the term "gliosis" due to long established association with neurodegenerative processes. In schizophrenic patients, earlier treatment with antipsychotic drugs has been correlated with better outcome (Loebel et al 1992), suggesting that antipsychotics may halt the degenerative processes occurring early in the

disease. We propose that induction of glial proliferation by antipsychotic drugs may be part of the mechanism that counteracts the transmitter imbalance in schizophrenia and other psychotic illness and helps to restore normal functional capacity.

Supported by Grant 44866 from the Center for Neuroscience of Mental Disorders, National Institute of Mental Health, Rockville, MD.

We thank B. Prinseva and J. Coburn for excellent technical assistance. Antipsychotic drugs were kindly provided by Smith Kline Beecham Pharmaceuticals, Pittsburgh, PA (chlorpromazine), Sandoz Pharmaceutical Co., East Hanover, NJ (clozapine), McNeil Pharmaceutical Co., Spring House, PA (haloperidol), Eli Lilly Co., Indianapolis, IN (olanzapine), Gate Pharmaceuticals, Sellersville, PA (pimozide), and Janssen Pharmaceutical Co., Titusville, NJ (risperidone).

References

- Alzaid K, Jones BD (1997): A case report of risperidone-induced obsessive-compulsive symptoms. *J Clin Psychopharmacol* 17:58-59.
- Arita J, Hashi A, Hoshi K, Mazawa S, Suzuki S (1998): D₂ dopamine-receptor-mediated inhibition of proliferation of rat lactotropes in culture is accompanied by changes in cell shape. *Neuroendocrinology* 68:163-171.
- Arnold SE, Franz BR, Trojanowski JQ, Moberg PJ, Gur RE (1996): Glial fibrillary acidic protein-immunoreactive astrogliosis in elderly patients with schizophrenia and dementia. *Acta Neuropathol* 91:269-277.
- Auchus AP, Pickel VM (1992): Quantitative light microscopic demonstration of increased pallidal and striatal met5-enkephalin-like immunoreactivity in rats after chronic treatment with haloperidol but not with clozapine: implications for the pathogenesis of antipsychotic-induced movement disorders. *Exp Neurol* 117:17-27.
- Benes FM, McSparren J, Bird ED, SanGiovanni JP, Vincent SL (1991): Deficits in small interneurons in prefrontal and cingulate cortices of schizophrenic and schizoaffective patients. *Arch Gen Psychiatry* 48:996-1001.
- Benes FM, Paskevich PA, Davidson J, Domesick VB (1985a): Synaptic rearrangements in medial prefrontal cortex of haloperidol-treated rats. *Brain Res* 348:15-20.
- Benes FM, Paskevich PA, Davidson J, Domesick VB (1985b): The effects of haloperidol on synaptic patterns in the rat striatum. *Brain Res* 329:265-274.
- Bergson C, Mrzljak L, Smiley JF, Pappy M, Levenson R, Goldman-Rakic PS (1995): Regional, cellular, and subcellular variations in the distribution of D₁ and D₅ dopamine receptors in primate brain. *J Neurosci* 15:7821-7836.
- Berthier ML, Kulisevsky J, Gironell A, Heras JA (1996): Obsessive-compulsive disorder associated with brain lesions: clinical phenomenology, cognitive function, and anatomic correlates. *Neurology* 47:353-361.
- Bruton CJ, Crow TJ, Frith CD, Johnstone EC, Owens DGC, Roberts GW (1990): Schizophrenia and the brain: a prospective clinico-neuropathological study. *Psychol Med* 20:285-304.
- Chakos MH, Lieberman JA, Bilder RM, Borenstein M, Lerner G, Bogerts B, et al (1994): Increase in caudate nuclei volumes of first-episode schizophrenic patients taking antipsychotic drugs. *Am J Psychiatry* 151:1430-1436.
- Chouinard G, Jones B, Remington G, Bloom D, Addington D, MacEwan GW, et al (1993): A Canadian multicenter placebo-controlled study of fixed doses of risperidone and haloperidol in the treatment of chronic schizophrenic patients. *J Clin Psychopharmacol* 13:25-40.
- Deutch AY, Moghaddam B, Innis RB, Krystal JH, Aghajanian GK, Bunney BS, et al (1991): Mechanisms of action of atypical antipsychotic drugs. Implications for novel therapeutic strategies for schizophrenia. *Schizophr Res* 4:121-156.
- Deutsch SI, Mastropalo J, Schwartz B, Rosse RB, Morihisa JM (1989): A glutamatergic hypothesis of schizophrenia. *Clin Neuropharm* 12:1-13.
- Drevets WC, Ongur D, Price JL (1998): Neuroimaging abnormalities in the subgenual prefrontal cortex: implications for the pathophysiology of familial mood disorders. *Mol Psychiatry* 3:220-226.
- Eddy MF, Walbroehl GS (1998): Recognition and treatment of obsessive-compulsive disorder. *Am Fam Physician* 57:1623-1634.
- Eriksson PS, Hansson E, Ronnback L. (1991): Mu and delta opiate receptors in neuronal and astroglial primary cultures from various regions of the brain—coupling with adenylate cyclase, localization on the same neurones and association with dopamine (D₁) receptor adenylate cyclase. *Neuropharmacology* 30:1233-1239.
- Farde L, Nordstrom AI, Wiesel FA, Pauli S, Halldin C, Sedvall G (1992): Positron emission tomographic analysis of central D₁ and D₂ dopamine receptor occupancy in patients treated with classical antipsychotics and clozapine. Relation to extrapyramidal side effects. *Arch Gen Psychiatry* 49:538-544.
- Gattaz WF, Gattaz D, Beckmann H (1982): Glutamate in schizophrenics and healthy controls. *Arch Psychiatr Nervenkr* 231:221-225.
- Goldman PS, Nauta WJH (1977): Columnar distribution of cortico-cortical fibers in the frontal association, limbic and motor cortex of the developing rhesus monkey. *J Comp Neurol* 171:369-386.
- Goldman-Rakic PS (1987): Circuitry of primate prefrontal cortex and regulation of behavior by representation memory. In: Plum, F (ed). *Handbook of Physiology, Vol. V, The Nervous System, Higher Functions of the Brain*, Bethesda: American Physiology Society, pp 373-417.
- Goldman-Rakic PS, Lidow MS, Smiley JF, Williams MS (1992): The anatomy of dopamine in monkey and human prefrontal cortex. *J Neural Trans* 36(suppl):163-177.
- Goldman-Rakic PS, Lidow M, Gallager DW (1990): Overlap of dopaminergic, adrenergic, and serotonergic receptor and complementarity of their subtypes in the primate prefrontal cortex. *J Neurosci* 10:2125-2138.
- Green MF, Marshall BD, Wirshing MD, Ames D, Marder SR, McGurk S, et al (1997): Does risperidone improve verbal working memory in treatment-resistant schizophrenia? *Am J Psychiatry* 154:799-804.
- Gur RE, Manny V, Mozley PD, Swanson C, Billar W, Gur RC (1998): Subcortical MRI volumes in neuroleptic-naive and treated patients with schizophrenia. *Am J Psychiatry* 155:1711-1717.
- Henn FA, Anderson DJ, Sellstrom A (1977) Possible relationship

- between glial cells, dopamine and the effects of antipsychotic drugs. *Nature* 266:637-638.
- Hyman SE, Arana GW (1987): *Handbook of Psychiatric Drug Therapy*. Boston: Little, Brown & Co.
- Jakab RL, Goldman-Rakic PS (1998): 5-Hydroxytryptamine_{2A} serotonin receptors in the primate cerebral cortex: possible site of action of hallucinogenic and antipsychotic drugs in pyramidal cell apical dendrites. *Proc Natl Acad Sci USA* 95:735-740.
- Kerns JM, Sierens DK, Kao LC, Klawans HL, Carvey PM (1992): Synaptic plasticity in the rat striatum following chronic haloperidol treatment. *Clin Neuropharmacol* 15:488-500.
- Kelley JJ, Gao XM, Tamminga CA, Roberts RC (1997): The effect of chronic haloperidol treatment on dendritic spines in the rat striatum. *Exp Neurol* 146:471-478.
- Keshavan MS, Haas GL, Kahn CE, Aguilar E, Dick EL, Schooler NR, Sweeney JA, Pettegrew JW (1998a): Superior temporal gyrus and the course of early schizophrenia: progressive, static, or reversible? *J Psychiatr Res* 32:161-167.
- Keshavan MS, Rosenberg D, Sweeney JA, Pettegrew JW (1998b): Decreased caudate volume in antipsychotic-naïve psychotic patients. *Am J Psychiatry* 155:774-778.
- Keshavan MS, Bagwell WW, Haas GI, Sweeney JA, Schooler NR, Pettegrew JW (1994): Changes in caudate volume with antipsychotic treatment. *Lancet* 344:1434.
- Kim JS, Claus D, Kornhuber HH (1983): Cerebral glutamate, antipsychotic drugs and schizophrenia: increase of cerebrospinal fluid glutamate levels and decrease of striate body glutamate levels following sulpiride treatment in rats. *Eur Neurol* 22:367-370.
- Kim JS, Dornhuber HH, Schmid-Beugk W, Holzmüller B (1980): Low cerebrospinal fluid glutamate in schizophrenic patients and a new hypothesis on schizophrenia. *Neurosci Lett* 20:379.
- Kinon BJ, Lieberman JA (1996): Mechanisms of action of atypical antipsychotic drugs: a critical analysis. *Psychopharmacology* 124:2-34.
- Kopala LC, Honer WG (1994): Risperidone, serotonergic mechanisms and obsessive-compulsive symptoms in schizophrenia. *Am J Psychiatry* 151:1714-1715.
- Kopala LC, Fredrikson D, Good KP, Honer WG (1996): Symptoms in antipsychotic-naïve, first-episode schizophrenia: response to risperidone. *Biol Psychiatry* 39:296-298.
- Krimer LS, Muly EC III, Williams GV, Goldman-Rakic PS (1998): Dopaminergic regulation of cerebral cortical microcirculation. *Nature Neurosci* 1:286-289.
- Lajiness ME, Chio CL, Huff RM (1993) D₂ dopamine receptor stimulation of mitogenesis in transfected Chinese hamster ovary cells: relationship to dopamine stimulation of tyrosine phosphorylations. *J Pharmacol Exp Ther* 267:1573-1581.
- Lidow MS, Goldman-Rakic PS (1994): A common action of clozapine, haloperidol, and remoxipride on D-1 and D-2 receptors in the primate cerebral cortex. *Proc Natl Acad Sci USA* 91:4356-4356.
- Lidow MS, Goldman-Rakic PS (1997): Differential regulation of D₂ and D₄ dopamine receptor mRNAs in the primate cerebral cortex vs. neostriatum: effects of chronic treatment with typical and atypical antipsychotic drugs. *J Pharmacol Exp Ther* 283:939-946.
- Lidow MS, Elsworth JD, Goldman-Rakic PS (1997): Down-regulation of the D₁ and D₅ dopamine receptors in the primate prefrontal cortex by chronic treatment with antipsychotic drugs. *J Pharmacol Exp Ther* 281:597-603.
- Lidow MS, Williams GV, Goldman-Rakic PS (1998): The cerebral cortex: a case for a common site of action of antipsychotics. *Trends Pharmacol Sci* 19:136-140.
- Lidsky TI, Yablonsky-Alter E, Zuck LG, Banerjee SP (1997): Antipsychotic drug effects on glutamatergic activity. *Brain Res* 764:46-52.
- Lindstrom E, van Knorring L (1994): Changes in single symptoms and separate factors of the schizophrenic syndrome after treatment with risperidone or haloperidol. *Pharmacopsychiatry* 27:108-113.
- Loebel AD, Lieberman JA, Alvir JM, Mayerhoff DI, Geisler SH, Szmanski SR (1992) Duration of psychosis and outcome in first-episode schizophrenia. *Am J Psychiatry* 149:1183-1188.
- Magistretti PJ, Pellerin L (1997): The cellular bases of functional brain imaging: evidence for astrocyte-neuron metabolic coupling. *The Neuroscientist* 3:361-365.
- Marder SR, Meibach RC (1994) Risperidone in the treatment of schizophrenia. *Am J Psychiatry* 151:825-835.
- Matsubara S, Matsubara R, Kusumi I, Koyami T, Yamashita I (1993): Dopamine D₁, D₂ and serotonin 2 receptors occupation by typical and atypical antipsychotic drugs in vivo. *J Pharmacol Exp Ther* 265:498-508.
- Meltzer HY, Lee MA, Ranjan R (1994): Recent advances in the pharmacotherapy of schizophrenia. *Acta Psychiatr Scand* 90(suppl 384):95-101.
- Meshul CK, Stallbaumer RK, Taylor B, Janowsky A (1994): Haloperidol-induced morphological changes in striatum are associated with glutamate synapses. *Brain Res* 648:181-195.
- Olney JW, Farber NB (1995): Glutamate receptor dysfunction and schizophrenia. *Arch Gen Psychiatry* 52:998-1007.
- Ongur D, Drevets WC, Price JL (1998): Glial reduction in the subgenual prefrontal cortex in mood disorders. *Proc Natl Acad Sci USA* 95:13290-13295.
- Pellerin L, Magistretti PJ (1996): Glutamate uptake into astrocytes stimulates aerobic glycolysis: a mechanism coupling neuronal activity to glucose utilization. *Proc Natl Acad Sci USA* 91:10625-10629.
- Pfieger FW, Barres BA (1997): Synaptic efficacy enhanced by glial cells in vitro. *Science* 277:1684-1687.
- Radewicz K, Garey LJ, Hirsch SR, Mortimer, AM, Hornstein, C, Bauer M, et al (1997): A neuroanatomical study of glial cells in schizophrenia. *Schizophr Res* 24:40-41.
- Rajkowska G, Selemon LD, Goldman-Rakic PS (1998): Neuronal and glial somal size in the prefrontal cortex: a post-mortem study of schizophrenia and Huntington's disease. *Arch Gen Psychiatry* 55:515-224.
- Rajkowska G, Selemon LD, Goldman-Rakic PS (1997): Marked glial neuropathology in prefrontal cortex distinguishes bipolar disorder from schizophrenia. *Schizophr Res* 24:41.
- Remington G, Adams M. (1997) Risperidone and obsessive-compulsive symptoms. *J Clin Psychiatry* 14:358-359.
- Roth BL, Craig SC, Choudhary MS, Uler A, Monsma FJ Jr, Shen Y, et al (1994): Binding of typical and atypical antipsychotic agents to 5-hydroxytryptamine-6 and 5-hy-

- doxytryptamine-7 receptors. *J Pharmacol Exp Ther* 268:1403-1410.
- Rothstein JD, Marin L, Levey AI, Dykes-Hoberg M, Jin L, Wu D, et al (1994): Localization of neuronal and glial glutamate transporters. *Neuron* 13:713-725.
- Saiardi A, Bozzi Y, Baik JH, Borrelli E (1997) Antiproliferative role of dopamine: loss of D₂ receptors causes hormonal dysfunction and pituitary hyperplasia. *Neuron* 19:115-126.
- Schrell UM, Fahlbusch R, Adams EF, Nomikos P, Reif M (1990): Growth of cultured human cerebral meningiomas is inhibited by dopaminergic agents. Presence of high affinity dopamine-D₁ receptors. *Clin Endocrinol Metab* 71:1669-1671.
- Seeman P (1990): Atypical neuroleptics: role of multiple receptors, endogenous dopamine, and receptor linkage. *Acta Psychiatr Scand Suppl* 358:14-20.
- Seeman P, Lee T, Chau-Wong M, Wong K (1976): Antipsychotic drug doses and antipsychotic/dopamine receptors. *Nature* 261:717-719.
- Seksel K, Lindeman MJ (1998): Use of clomipramine in the treatment of anxiety-related and obsessive-compulsive disorders in cats. *Aust Vet J* 76:317-321.
- Selemon LD, Rajkowska G, Goldman-Rakic PS (1998): Elevated neuronal density in prefrontal area 46 in brains from schizophrenic patients: application of a 3-dimensional, stereologic counting method. *J Comp Neurol* 392:402-412.
- Selemon LD, Lidow MS, Goldman-Rakic PS (1997): Chronic neuroleptic drug treatment induces mild gliosis in the prefrontal cortex of rhesus monkeys. *Schizophr Res* 24:266-267.
- Selemon LD, Rajkowska G, Goldman-Rakic PS (1995): Abnormally high neuronal density in the schizophrenic cortex: a morphometric analysis of prefrontal area 9 and occipital area 17. *Arch Gen Psychiatry* 52:805-818.
- Selemon LD, Goldman-Rakic PS (1988): Common cortical and subcortical targets of the dorsolateral prefrontal and posterior parietal cortices in the rhesus monkey: evidence for a distributed neural network subserving spatially guided behavior. *J Neurosci* 8:4049-4068.
- Stafford JE, Jackson LS, Forrest TJ, Barrow A, Palmer RF (1981): Haloperidol pharmacokinetics: a preliminary study in rhesus monkeys using a new radioimmunoassay procedure. *J Pharmacol Methods* 6:261-279.
- Stevens JR (1982): Neuropathology of schizophrenia. *Arch Gen Psychiatry* 39:1131-1139.
- Sumiyoshi T, Kido H, Sakamoto H, Urasaki K, Suzuki K, Yamaguchi N, et al (1994): In vivo dopamine-C-2 and serotonin-5-HT₂ receptor binding study of risperidone and haloperidol. *Pharmacol Biochem Behav* 47:553-557.
- Swoboda KJ, Jenike MA (1995): Frontal abnormalities in a patient with obsessive-compulsive disorder: the role of structural lesions in obsessive-compulsive behavior. *Neurology* 45:2130-2134.
- Tamminga CA (1998): Schizophrenia and glutamatergic transmission. *Crit Rev Neurobiol* 12:21-36.
- Vincent SL, Adamec E, Sorensen I, Benes FM (1994): The effects of chronic haloperidol administration on GABA-immunoreactive axon terminals in rat medial prefrontal cortex. *Synapse* 17:26-35.
- Vincent SL, Khan Y, Benes FM (1993) Cellular distribution of dopamine D₁ and D₂ receptors in rat medial prefrontal cortex. *J Neurosci* 13:2552-2564.
- Vincent SL, McSparren J, Want RY, Benes FM (1991): Evidence for ultrastructural changes in cortical axodendritic synapses following long-term treatment with haloperidol or clozapine. *Neuropsychopharmacology* 5:147-155.
- Walker AE (1940): A cytoarchitectural study of the prefrontal area of the macaque monkey. *J Comp Neurol* 73:59-86.
- Williams RW, Rakic P (1988): Three-dimensional counting: an accurate and direct method to estimate numbers of cells in sectioned material. *J Comp Neurol* 278:344-352.
- Yamaguchi H, Aiba A, Nakamura K, Nakao K, Sakagami H, Goto K, et al (1996): Dopamine D₂ receptor plays a critical role in cell proliferation and proopiomelanocortin expression in the pituitary. *Genes Cells* 1:253-268.
- Yasunari K, Kohno M, Hasuma T, Horio T, Kano H, Yokokawa K, et al (1997): Dopamine as a novel antimigration and antiproliferative factor of vascular smooth muscle cells through dopamine D₁-like receptors. *Arterioscler Thromb Biol* 17:3164-3173.
- Zhang Y, Cincotta AH (1997): Inhibitory effects of bromocriptine on vascular smooth muscle cell proliferation. *Atherosclerosis* 133:37-44.