

The Neurobiological Effects of Electroconvulsive Therapy Studied Through Magnetic Resonance: What Have We Learned, and Where Do We Go?

Olga Therese Ousdal, Giulio E. Brancati, Ute Kessler, Vera Erchinger, Anders M. Dale, Christopher Abbott, and Leif Oltegal

ABSTRACT

Electroconvulsive therapy (ECT) is an established treatment choice for severe, treatment-resistant depression, yet its mechanisms of action remain elusive. Magnetic resonance imaging (MRI) of the human brain before and after treatment has been crucial to aid our comprehension of the ECT neurobiological effects. However, to date, a majority of MRI studies have been underpowered and have used heterogeneous patient samples as well as different methodological approaches, altogether causing mixed results and poor clinical translation. Hence, an association between MRI markers and therapeutic response remains to be established. Recently, the availability of large datasets through a global collaboration has provided the statistical power needed to characterize whole-brain structural and functional brain changes after ECT. In addition, MRI technological developments allow new aspects of brain function and structure to be investigated. Finally, more recent studies have also investigated immediate and long-term effects of ECT, which may aid in the separation of the therapeutically relevant effects from epiphenomena. The goal of this review is to outline MRI studies (T1, diffusion-weighted imaging, proton magnetic resonance spectroscopy) of ECT in depression to advance our understanding of the ECT neurobiological effects. Based on the reviewed literature, we suggest a model whereby the neurobiological effects can be understood within a framework of disruption, neuroplasticity, and rewiring of neural circuits. An improved characterization of the neurobiological effects of ECT may increase our understanding of ECT's therapeutic effects, ultimately leading to improved patient care.

<https://doi.org/10.1016/j.biopsych.2021.05.023>

Major depressive disorder is a leading cause of disability worldwide, ranked among the top 10 causes of disability-adjusted life-years in people aged 10–49 years (1). Although efficient pharmacological and psychological treatments have been available for decades, a significant proportion of patients do not respond sufficiently to these first-line treatments, and relapse rates are high (2). Notably, these patients may benefit from electroconvulsive therapy (ECT), which is still regarded as the most effective treatment for severe or treatment-resistant depressive episodes (3). The ECT procedure is completed under general anesthesia, when electric currents are passed through the brain, intentionally triggering a brief seizure. It is typically administered 2–3 times per week, with the average patient requiring a range of 6–12 treatments (4). Despite the well-documented clinical efficacy, ECT's mechanism of action remains poorly understood. Preclinical animal models have contributed substantially to our understanding of the neurobiological effects, which include observations of altered monoaminergic transmission, stimulation of neuroendocrine systems, immune system activation, and augmented neuroplasticity (5,6). However, the results of these models cannot be directly translated to human populations. As such, neuroimaging, especially magnetic resonance imaging (MRI), is an important tool to improve our understanding of ECT's neurobiological and eventually clinically relevant effects.

Over the past couple of decades, an increasing number of studies have investigated the neurobiological effects of ECT through the use of MRI. The earliest studies were mainly concerned with ECT causing brain damage (7–9), which could be reflected in signs of reactive gliosis or edema. While some accumulation of extracellular tissue fluid may be present (10), the majority of studies have failed to support post-ECT gliosis or global brain edema (11–13) even after lengthy courses of ECT (14). In contrast to early work, more recent MRI studies have focused on ECT's mechanisms of action. However, many of these investigations have considerable limitations related to a selective focus on a few regions of interest (ROIs), underpowered samples, unstructured treatment algorithms, and heterogeneity in clinical and sociodemographic characteristics of the included subjects. Accordingly, the results of these neuroimaging studies vary considerably, in terms of both the distribution and the extent of findings, and should be addressed in studies synthesizing existing evidence.

Here, we review anatomical and molecular MRI (including T1-weighted imaging, proton magnetic resonance spectroscopy, and diffusion-weighted imaging [DWI]) studies of ECT in depression. Information regarding the search strategy and the included studies can be found in the [Supplement](#). We also discuss emerging areas of study, including mega-analyses,

machine learning, innovative MRI techniques, and extended data sampling, which ultimately may lead to a deeper understanding of ECT's neurobiological effects. Based on the reviewed literature, we propose a model that directly incorporates the immediate disruptive effects of the electrical stimulation and seizure, which are well-known aspects of ECT usually not accounted for in contemporary models. The immediate disruptive effects are followed by temporarily enhanced neuroplasticity, which enables the brain to rewire in more optimal patterns over time. We end by outlining several testable predictions of this mechanistic model and suggest new imaging studies, which eventually may improve our understanding of the ECT's therapeutic actions.

IMPAIRED NEUROPLASTICITY IN DEPRESSION

Brain plasticity is a generic term that refers to the brain's ability to change and adapt as a result of experience. It is seen at multiple levels, including molecular and cellular alterations, synaptic connectivity, and changes in large-scale brain networks. Depression has been characterized by a failure or downregulation of neuroplasticity (15,16). This is based on work in animal models showing reduced dendritic complexity and synaptic loss in the prefrontal cortex (PFC) and the hippocampus (17,18), respectively, as well as impaired hippocampal neurogenesis (19). Equivalently, postmortem investigations in subjects with depression have demonstrated reduced number of granule cells in the dentate gyrus, a stem-cell containing niche of the hippocampus (20,21), and reduced neuronal size and number of spine synapses in the PFC (22). These microanatomical changes may translate into volumetric reductions of gross anatomical ROIs measured using MRI. Accordingly, reduced hippocampal and PFC volume are two of the most replicated findings in MRI studies of depression, especially in patients experiencing an early onset or recurrent episodes (23,24). Depression is also associated with changes in the functional and structural connectivity of large-scale brain networks (25–27). Interestingly, such network alterations have recently been linked to lower synaptic density in a combined synaptic vesicle glycoprotein 2A (SV2A) ligand positron emission tomography and MRI study (28), suggesting a plausible biological underpinning. The cellular and neuroimaging findings are presumed to result from decreased levels of neurotrophins (16,29) and altered levels of proinflammatory cytokines (30) possibly related to stress and hypercortisolemia (16,31). Although speculative, a lower plastic potential may impair cognitive flexibility and the regulatory control of stimulus-driven affective processing (32), which may translate into the rigidity and repetitive negative thought patterns commonly seen in depression.

MRI STUDIES OF ECT IN DEPRESSION

T1 Structural MRI

Recent theoretical conceptualizations suggest that antidepressants, including ECT, may act through reversing a neuroplasticity deficit in depression (33,34). Given that MRI volumetric reductions in depression to some extent reflect reduced or impaired neuroplasticity, successful treatment may reverse these volumetric deficits. ECT-mediated changes of

gray matter are derived from T1-weighted images acquired before and after treatment and estimated using either a data-driven whole-brain approach or an ROI approach. The majority of volumetric studies have focused on temporal lobe structures, most notably the hippocampus and the amygdala. These studies generally observed an increase in hippocampus and/or amygdala volume after treatment (12,35–59), although a few exceptions exist (8,9,60). The findings are further corroborated by recent meta- and mega-analyses reporting volume increases up to 4%–5% (61,62) for the hippocampus and 5%–6% (63) for the amygdala. The volumetric expansions are positively associated with number of ECTs (61) and may be mediated, at least partly, by the strength of the electrical field (64). The volumetric changes have been further delineated to mainly the gray matter subfields of the hippocampus (37,39,49,65–67) and the basolateral nuclei of the amygdala (39).

Beyond the hippocampus-amygdala complex, increase of gray matter volume or cortical thickness in temporal cortex (36,39,41,44,50,53,68,69), insula (36,39,41,44,53,69,70), anterior cingulate cortex (36,38,41,50,55,68,70), medial prefrontal cortex (41,53,68), striatum (36,39,45,46,71,72), postcentral gyrus (41,73), fusiform gyrus (68,70), limbic cerebellum (74), and the supplementary motor cortex (73) have also been reported after treatment. As most studies used a right unilateral electrode placement, findings are more frequently reported in the right hemisphere, which aligns with the distribution of electric field strength (64). Together, the results of these studies indicate volumetric enlargement of several cortico-limbic brain regions (Figure 1A); however, until recently, the pattern of whole-brain structural alterations after ECT remained unresolved.

Thus, to investigate changes in whole-brain gray matter, the Global ECT-MRI Research Collaboration performed a multisite mega-analysis of individual-level subject data. With the largest sample size to date ($N = 328$), the authors reported gray matter volumetric changes in most cortical and subcortical ROIs, with the exception of the cerebellum (75). The volumetric expansion of all subcortical ROIs negatively correlated with total ventricle size, indicating that the increase of subcortical gray matter may be at the expense of cerebrospinal fluid spaces. The study explains why earlier work suggested anatomical specificity of gross volumetric effects, which could be due to their limited statistical power to detect the full range of gray matter change. Furthermore, the results suggest that morphological alterations in the immediate aftermath of treatment are not restricted to specific depression circuits but instead may represent a mixture of therapeutically relevant and nonrelevant effects.

In addition to the focus on a selected number of ROIs, most studies have compared baseline MRIs with MRIs acquired within 2 weeks after treatment completion. Understanding the time-dependency of the MRI effects is important, as this may point toward their neurobiological underpinning as well as their clinical relevancy. Based on a limited number of studies, volumetric increases could be present already after two ECT sessions (52), with further increases after the remainder of the ECT series (52). Moreover, existing evidence suggests that the volumetric expansions are transient, with a return to baseline of both the hippocampal and PFC volumes by 3–12 months

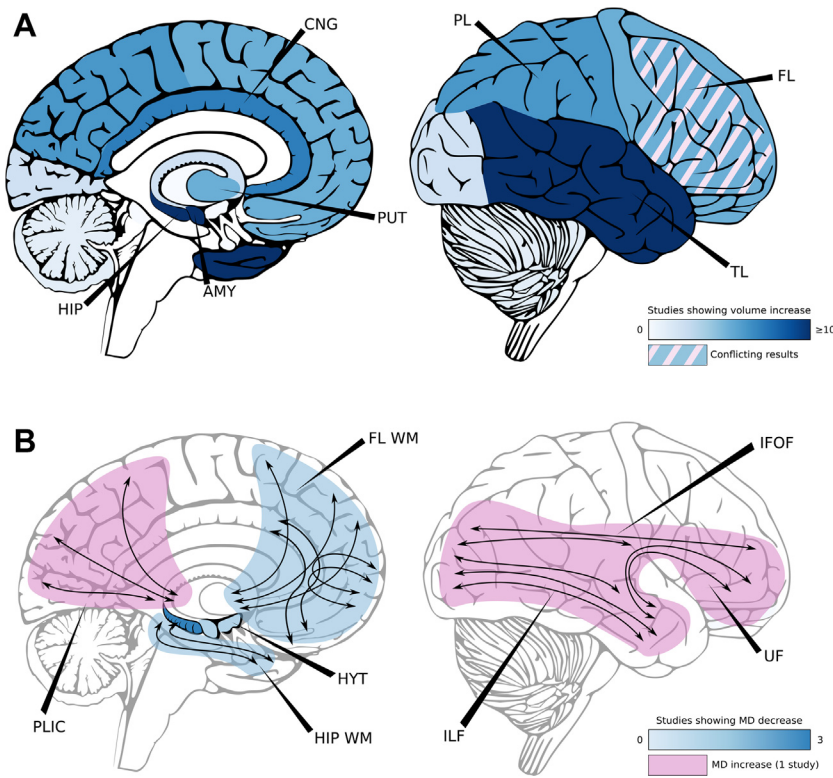


Figure 1. Density of studies reporting electroconvulsive therapy–related volume and mean diffusivity (MD) changes. **(A)** Summary of T1 magnetic resonance imaging studies reporting whole-brain or regional volumetric increases (blue color) before and after electroconvulsive therapy. Color intensity refers to the number of studies reporting volumetric increase for the anatomical region. Shaded areas indicate conflicting results. Results from different hemispheres were combined. **(B)** Summary of diffusion-weighted imaging studies reporting changes in MD before and after electroconvulsive therapy. Blue color indicates MD decrease, while red color indicates MD increase. Color intensity refers to the number of studies reporting MD changes in the anatomical region. Results from different hemispheres were combined. AMY, amygdala; CNG, cingulate cortex; FL, frontal lobe; FL WM, anterior thalamic radiations, minor forceps, and anterior cingulum bundle; HIP, hippocampus; HIP WM, hippocampal white matter tracts; HYT, hypothalamus; IFOF, inferior fronto-occipital fasciculus; ILF, inferior longitudinal fasciculus; PL, parietal lobe; PLIC, posterior limb of the internal capsule; PUT, putamen; TL, temporal lobe; UF, uncinata fasciculus.

(35,45,53,65,66,76). Notably, no study has investigated the full spectrum of anatomical ROIs; thus, it remains to be established whether the return to baseline is global or shows regional specificity. In addition, extended data sampling from individual subjects will be necessary to understand the emergence and resolution of the structural effects at a finer scale and at the individual level.

How the changes in gray matter indices relate to clinical response remains debated. Some of the earliest studies reported a correlation between baseline hippocampal volume or the hippocampal volumetric increase and the reduction in depressive symptoms (38,52). However, the majority of studies have failed to find an association (35,42,45,47,48,50,51,59,61,64,75). The lack of association could be related to the notion that the hippocampus is a heterogeneous entity. Thus, clinical response may selectively pertain to structural changes in anterior subregions (77) or the dentate gyrus (67,78). Beyond the hippocampal complex, the baseline volume or the volumetric change of several cortical [i.e., orbitofrontal (53), inferior frontal gyrus (79)], anterior cingulate cortex (38,40,50), temporal (50,68), insula (69), and subcortical [amygdala (52), striatum (46,71)] ROIs have also been linked to the clinical efficacy of ECT, yet these varying findings generally await replication in larger samples. Alternatively, clinical effect may be driven by the simultaneous change of several anatomical regions, which could be tested through the use of machine learning. The majority of machine learning studies so far have been modestly successful, using volumetric change (80), baseline surface-based morphometry (81,82), or

multimodal fusion (83). With refinement of analyses and larger sample sizes, these methods may bring novel insight into possible anatomical correlates of clinical response.

Diffusion-Weighted Imaging

Studies of whole-brain or regional gray matter volume changes on ECT treatment are important; however, they do not inform us regarding the underlying tissue properties. Thus, to understand the biological underpinning of the volumetric changes, DWI can be useful. DWI measures the restriction of freely moving water molecules in tissue and uses these restrictions to infer the organization of the tissue. If modeled with an ellipsoid shape, represented by a tensor, metrics such as fractional anisotropy (FA), mean diffusivity (MD), radial diffusivity, and axial diffusivity can be derived (84–86).

With regard to brain white matter, early work suggested a significant increase in FA of the anterior cingulum, forceps minor, and left superior longitudinal fasciculus after the treatment series (87), in addition to a more general increase in frontal white matter FA (88) (Figure 1B). While biologically unspecific, the increased FA supported increased integrity of white matter tracts in these cortic limbic regions. However, the findings have not been replicated in more recent studies (10,60,89), which instead showed increased MD in widespread white matter tracts (10,89) (Figure 1B). At the microstructural level, increased MD may represent an increase in the amount of extracellular fluid in white matter or alternatively reduced integrity of the white matter parenchyma itself

(84). The clinical translation of the DWI findings is presently limited. Early work found treatment-related increases in FA and decreases in MD in dorsal frontolimbic circuits to be associated with decreased depression severity (87). However, subsequent whole-brain studies failed to find any associations between white matter MD or FA and clinical response (10,60,89).

Although mostly used to delineate brain white matter, DWI can also be used to investigate gray matter properties. Accordingly, a reduction of average gray matter MD in amygdala and hippocampal ROIs is consistently reported (59,90,91) after ECT (Figure 1B). Reduced MD has also been observed in anterior hippocampal pathways (92). The reduction is not observed after one ECT session (92) or at 4 weeks after treatment (59). Moreover, it may be independent of the concomitant volumetric expansion of these anatomical regions (91). Reduced gray matter MD suggests a shift in tissue properties with an increased proportion of water molecules in compartments with more restricted diffusion and may signify an increase in the number of cells, dendrites, or axons in the amygdala and the hippocampus (84). Similar to white matter DWI investigations, studies linking amygdala and/or hippocampus MD and clinical response have also produced mixed results (59,90–92).

Magnetic Resonance Spectroscopy

Changes in brain macro- and microstructure are likely to be preceded or followed by changes in brain metabolites. In humans, concentrations of metabolites in the brain can be measured using proton magnetic resonance spectroscopy. Measurements are performed within a specific volume, a voxel, with the anatomical placement varying between studies (i.e., hippocampal, anterior cingulate cortex, prefrontal cortex, or occipital cortex). Although results are mixed (55,93–101), and many studies do not report on all metabolites within the spectra, a reduction in *N*-acetylaspartate (NAA) was reported in six studies (55,95,98–101). The finding is difficult to reconcile with a theory that only comprises plasticity enhancing effects (102). A decrease in NAA is often paralleled by an increase in choline in clinical radiology, and increased choline has indeed been reported by some proton magnetic resonance spectroscopy investigations (93,94,101) after ECT. Although two studies reported increased NAA in responders only (95,97), alterations in NAA have generally not been associated with clinical response.

The seizure threshold is known to increase during an ECT treatment series (103,104), which supports the hypothesis that ECT mediates antidepressant efficacy through anticonvulsive mechanisms (105). Increased GABAergic (gamma-aminobutyric acidergic) transmission would provide additional support for ECT's anticonvulsant properties. Early work supported this notion with increased GABA concentrations after an ECT series (106). However, more recent work has not found significant changes in GABA on treatment completion (99,107). In contrast, ECT may affect excitatory neurotransmission (55,95–97,100,101,108), which is suggested by recent studies reporting an increase in glutamate or Glx (glutamate+glutamine) after ECT (96,97,100,101,108).

THE BIOLOGICAL SIGNIFICANCE OF THE MRI FINDINGS

Several biological processes have been proposed to underlie the MRI structural effects, but among them, neuroplasticity, including augmented neurogenesis, has received most attention recently. The neuroplasticity hypothesis is based on work in preclinical animal models suggesting a dose-dependent increase of neurogenesis in the dentate gyrus of the hippocampus after electroconvulsive stimulation [the animal model of ECT (109)]. Importantly, interfering with this neurogenic process blocks the antidepressant effect (110) [but see (111)]. Although increased neurogenesis may not be exclusive to ECT treatment, the neurogenic effect of electroconvulsive stimulation exceeds that of antidepressant medications, and the onset is faster, being comparable to the superior and fast onset effects of ECT (112). ECT may operate by inducing neurogenesis in humans as well; however, neurogenesis is not likely to be the main mediating factor of the T1 gray matter volumetric effects. First, the volumetric changes induced by neurogenesis are expected to be microscopic and confined to a few anatomical structures (113,114). Thus, neurogenesis cannot explain the global volumetric changes reported in recent MRI studies. Second, discrepant hippocampal volumes in animal models of depression are largely explained by differences in neuropil and glial cell numbers, while deficits in neuronal number contributes to a lesser extent (115). Third, the timing of effects makes neurogenesis as the principal mediator of the volumetric changes unlikely. While structural changes may be seen even after two ECT sessions (52), the maturation, migration, and integration of newborn neurons into functional circuits takes place over several months (116).

Beyond neurogenesis, a plethora of other plastic processes have been reported in animal models of ECT, including synaptogenesis, dendrogenesis, dendritic arborization, gliogenesis, mossy fiber sprouting, and angiogenesis (117–119). Notably, these neuroplastic processes are closely interconnected through the actions of trophic factors and are not restricted to the hippocampal complex. Among the various plastic processes, shifts in cumulative length of dendrites and dendritic spine density have recently been associated with the gray matter density signal in voxel-based morphometry (120) or gray matter volume (121). This is arguably in line with studies linking electrical field strength to dendritic arborization in animal models (122). Moreover, MRI-detectable volumetric changes in relation to psychopathology and learning have both been correlated with the synaptic marker GAP43 (123,124), which is essential for the growth, regeneration, and function of neurites (i.e., dendrites and axons). These various lines of evidence suggest an effect of ECT on neurites, which accords with the DWI studies investigating gray matter properties.

Although commonly interpreted to reflect augmented neuroplasticity, the volumetric expansions could also reflect fluid shifts. Indeed, the volumetric changes may be driven by changes in blood flow, as the T1 relaxation times for arterial blood and gray matter are not clearly distinguishable (125). Accordingly, a recent study using arterial spin labeling reported that ROIs with significant volumetric enlargements also exhibited increased blood flow after ECT (126). Alternatively, an increase of fluids in the extracellular space (i.e., vasogenic

edema) secondary to the hypertensive surge and a possible breach of the blood-brain barrier (127) could also explain the volumetric expansion. However, this is not supported by studies investigating gray matter MD, which instead suggest an increased volume fraction of more restricted water pools in subcortical gray matter after treatment (59,90,91). Although speculative, the findings may reflect neuroplastic changes leading to greater occupation and hence restriction of water molecules in the extracellular space (84,85). Taken together, a multitude of plastic processes may contribute to the MRI-like plasticity after ECT; however, the type and extent remain undetermined and may show regional variability. As such, brain regions exhibiting the greatest volumetric alterations may be those subjected to several plastic processes, which makes gross volumetric change more readily detectable (128).

Notably, not all MRI findings fit with the neuroplasticity conceptualization, and indeed, there is evidence to support that ECT also has transient disruptive effects on brain function and structure. Early work in animal models reported electroconvulsive stimulation to cause a reversible loss of long-term potentiation (LTP) in the hippocampus (129,130). LTP is a process by which synaptic connections are strengthened, producing a long-lasting increase in signal transmission between neurons. Because LTP is likely to be the process by which information is stored in the brain, a temporary loss of LTP may be related to some of ECT's side effects (e.g., confusion, amnesia). More importantly, these preclinical and clinical observations support a temporary disruption of brain function on treatment. Likewise, reports of decreased levels of NAA (55,95,98–101) [and, to some extent, increased levels of choline (93,94,101)] are also difficult to reconcile with a mechanistic model that only entails plasticity enhancing effects. A decrease in the NAA peak suggests reduced neuronal integrity after ECT (131). Notably, reduced neuronal integrity is likely to affect the connectivity of large-scale neuronal networks. Although not included in this review, several studies have indeed reported reduced resting-state functional connectivity after ECT (132–134), which in some patients may be paralleled by changes in corresponding structural pathways (10). Notably, reduced functional connectivity has been related to cognitive side effects by some (134). As such, the brain disruptive effects may underlie both the rapid clinical response and the side effects, which is further suggested by studies reporting associations between duration of postictal confusion and clinical outcome (135) as well as between postictal confusion and ECT-mediated cognitive impairments (136). The temporary disruption may act on neural circuits, which promotes the rigid negative bias of attention, memory, interpretations, and self-representations, allowing these to rewire in nondepressed states (32). However, disruption beyond the neural circuits maintaining depressive symptoms [likely related to dose (137)] may add side effects without further symptom reduction.

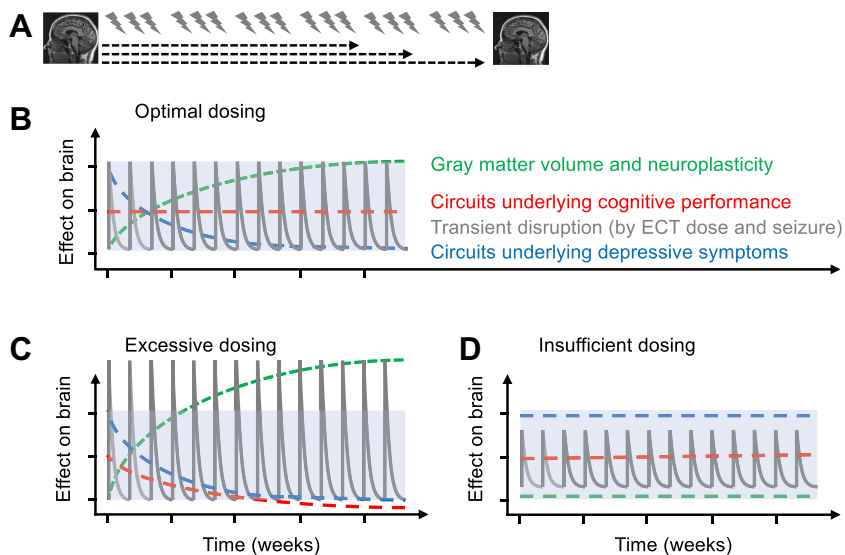
CONCLUSION AND FUTURE DIRECTIONS

This review focuses on MRI structural and biochemical changes associated with ECT. Based on the reviewed literature, we show that ECT causes broad volumetric expansions of brain gray matter in the post-treatment phase, which is likely to

represent a mixture of therapeutic and nontherapeutic ECT-induced effects. Accordingly, attempts to link the gray matter volumetric changes to clinical response have produced mixed results. Measurements of gray matter diffusivity suggest that the changes are not due to fluid shifts, but instead represent plastic changes in the parenchyma itself. However, the exact biological underpinning of the volumetric expansions remains to be established. In contrast, investigations of the brain's metabolite spectra, white matter properties, and functional connectivity suggest that ECT also has disruptive effects. Thus, we propose a mechanistic model, which includes a temporary disruption followed by augmented neuroplasticity and rewiring (Figure 2A, B). Indeed, while neuroplastic effects have been postulated before, we here suggest a sequential model that includes the cause and the consequence of the neuroplasticity enhancement. Notably, there are likely to be optimal levels of disruption and neuroplasticity, which produces sufficient antidepressant response with minimal side effects, and these optimal levels may be related to ECT dose (i.e., electric stimulation and seizure characteristics). Thus, ECT dose may have to be individually tailored to obtain remission while simultaneously ensuring cognitive safety (Figure 2C, D).

While the theoretical basis and the indirect evidence for our model may at first seem compelling, the model needs to be tested more rigorously in future studies. These studies should aim to study the brain at a higher resolution, which is made possible by some of the latest advances in MRI acquisition, image processing, and modeling. Combined with animal studies, such methods may delineate the biological processes, one element at a time. Alterations in synaptic connections may be assessed by studies of the individual functional connectome (138–140), preferably in combination with SV2A ligand positron emission tomography, which (indirectly) measures synaptic densities. We hypothesize that ECT's disruptive effects lead to a loss of individual connectome stability early in the treatment course, possibly reflecting changes in interneuronal communication at the level of brain synapses (129,130). These effects may be paralleled by regional reductions of SV2A density. Moreover, we propose that the disruption and neuroplasticity enhancement should be linked; thus, the degree of connectome instability early in the treatment course should predict later increases in regional synaptic density as measured by SV2A ligand positron emission tomography. To further investigate neuroplasticity, we suggest using the latest advances in DWI, which combine multishell acquisition with refined modeling [e.g., neurite orientation dispersion and density imaging (141), restricted spectrum imaging (142), and spherical mean technique multicompartments (143)]. These techniques may provide valuable information regarding changes in the amount of neuropil after ECT treatment and may show cumulative effects over the course of an ECT treatment series. Finally, although the electrical field seems important for the gray matter changes (64), the role of the seizure characteristics needs further study (144,145).

Notably, existing studies of ECT's morphometric and biochemical effects have produced mixed results, which is likely to reflect clinical and demographic differences between the data samples in combination with different data processing and analyses pipelines. The variability of results is reinforced by the small sample sizes of most studies. Thus, to increase



disruptive effects is a temporary enhancement of neuroplasticity (green line), which may lead to an increase in volume of gray matter (green line). The disruption and neuroplastic effects in combination lead to rewiring of neural circuits underlying depressive symptoms (blue line). The disruption and neuroplastic effects in combination lead to rewiring of neural circuits underlying depressive symptoms (blue line). The disruption and neuroplastic effects in combination lead to rewiring of neural circuits underlying depressive symptoms (blue line). Note that the lines represent mean change over time and are not necessarily representative of each ECT session. (C) Excessive ECT dosing (high electric field strength, very long seizure duration) will result in long postictal recovery, more widespread disruptive effects (affecting circuits implicated in depression and cognition), and possibly more extensive volumetric effects. The clinical outcome will be antidepressant response with cognitive impairment. (D) Insufficient ECT dosing (low electric field strength, very short seizure duration) will result in short postictal recovery times, limited disruption, and insufficient changes in neuroplasticity. The clinical outcome will be minimal antidepressant response and no side effects.

replication, there is a need for prospective collaborative efforts aiming to collect harmonized in-depth clinical and demographic information, as well as using a harmonized imaging protocol. In addition, attempts to harmonize the way ECT is administered, including electric dosage and electrode placement, will also be important to discover the neurobiological mechanisms related to its therapeutic action.

In summary, although preclinical animal models have been useful in understanding the working mechanisms of ECT in depression, human MRI studies are important to delineate which aspects can be translated and which aspects may be unique to human populations. Based on the reviewed literature, we propose a model in which brain disruption, plasticity potentiation, and rewiring occur in sequence and ultimately explain immediate, short-, and long-term effects of ECT. Although evidence for our model is indirect, it may be a framework for understanding the neurobiological underpinning of ECT's therapeutic effects and derive new testable hypotheses, which ultimately may bring the field forward.

ACKNOWLEDGMENTS AND DISCLOSURES

This work was supported by the Western Norway Regional Health Authority (Grant No. 91223 [to LO] and Grant No. 912275 [to OTO]) and National Institute of Mental Health (Grant Nos. U01MH111826 and R61MH125126 [to CA]).

AMD is a founder of and holds equity in CorTechs Labs, Inc., and serves on its Scientific Advisory Board; is a member of the Scientific Advisory Board of Human Longevity, Inc.; and receives funding through research agreements with General Electric Healthcare and Medtronic, Inc. All other authors report no biomedical financial interests or potential conflicts of interest.

Figure 2. Disrupt, potentiate, and rewire. This figure illustrates the proposed mechanistic model. The model assumes that the subject has the potential to respond to electroconvulsive therapy (ECT) and does not address nonresponse despite adequate dosing. (A) Exemplary Electroconvulsive Therapy-Magnetic Resonance Imaging study protocol. Number of ECTs depends on the clinical response and judgment of the treating ECT practitioner and are usually performed within a period of 2–6 weeks (→). Magnetic resonance imaging is typically acquired within 1 week before and within 2 weeks after the treatment series. (B) Proposed model integrating the effects of ECT at ideal dosing. Before treatment (left side of x-axis), the brain is in a depressed state, characterized by high symptom load and possibly low plastic potential (reduced neurotrophic factors). Each session of ECT (electrical stimulation and seizure) constitutes a temporary disruption (gray curve; peaks with exponential decay) of brain function (postictal confusion, etc.) with corresponding physiological effects (reduced *N*-acetylaspartate, functional connectivity, and white matter integrity). The brain's response to the

ARTICLE INFORMATION

From the Mohn Medical Imaging and Visualization Centre (OTO, VE, LO), Department of Radiology, and NORMENT (UK), Division of Psychiatry, Haukeland University Hospital; and Centre for Crisis Psychology (OTO), Faculty of Psychology, and Department of Clinical Medicine (UK, VE, LO), University of Bergen, Bergen, Norway; Department of Clinical and Experimental Medicine (GEB), University of Pisa, Pisa, Italy; Center for Multimodal Imaging and Genetics (AMD), Department of Radiology (AMD), and Department of Neurosciences (AMD), University of California San Diego, La Jolla, California; and Department of Psychiatry (CA), University of New Mexico, Albuquerque, New Mexico.

Address correspondence to Olga Therese Ousdal, M.D., Ph.D., at olgetherese.ousdal@gmail.com or olga.therese.ousdal@helse-bergen.no, or Leif Olteidal, M.D., Ph.D., at leif.olteidal@k1.uib.no.

Received Dec 20, 2020; revised and accepted May 12, 2021.

Supplementary material cited in this article is available online at <https://doi.org/10.1016/j.biopsych.2021.05.023>.

REFERENCES

- GBD 2019 Diseases and Injuries Collaborators (2020): Global burden of 369 diseases and injuries in 204 countries and territories, 1990–2019: A systematic analysis for the Global Burden of Disease Study 2019. *Lancet* 396:1204–1222.
- Rush AJ, Trivedi MH, Wisniewski SR, Nierenberg AA, Stewart JW, Warden D, *et al.* (2006): Acute and longer-term outcomes in depressed outpatients requiring one or several treatment steps: A STAR*D report. *Am J Psychiatry* 163:1905–1917.
- UK ECT Review Group (2003): Efficacy and safety of electroconvulsive therapy in depressive disorders: A systematic review and meta-analysis. *Lancet* 361:799–808.
- Brus O, Cao Y, Gustafsson E, Hultén M, Landén M, Lundberg J, *et al.* (2017): Self-assessed remission rates after electroconvulsive therapy of depressive disorders. *Eur Psychiatry* 45:154–160.

5. Bolwig TG (2011): How does electroconvulsive therapy work? Theories on its mechanism. *Can J Psychiatry* 56:13–18.
6. van Buel EM, Patas K, Peters M, Bosker FJ, Eisel UL, Klein HC (2015): Immune and neurotrophin stimulation by electroconvulsive therapy: Is some inflammation needed after all? *Transl Psychiatry* 5:e609.
7. Coffey CE, Figiel GS, Djang WT, Sullivan DC, Herfkens RJ, Weiner RD (1988): Effects of ECT on brain structure: A pilot prospective magnetic resonance imaging study. *Am J Psychiatry* 145:701–706.
8. Coffey CE, Weiner RD, Djang WT, Figiel GS, Soady SA, Patterson LJ, *et al.* (1991): Brain anatomic effects of electroconvulsive therapy. A prospective magnetic resonance imaging study. *Arch Gen Psychiatry* 48:1013–1021.
9. Puri BK, Oatridge A, Saeed N, Ging JE, McKee HM, Lekh SK, Hajnal JV (1998): Does electroconvulsive therapy lead to changes in cerebral structure. *Br J Psychiatry* 173:267.
10. Repple J, Meinert S, Bollettini I, Grotegerd D, Redlich R, Zaremba D, *et al.* (2020): Influence of electroconvulsive therapy on white matter structure in a diffusion tensor imaging study. *Psychol Med* 50:849–856.
11. Szabo K, Hirsch JG, Krause M, Ende G, Henn FA, Sartorius A, Gass A (2007): Diffusion weighted MRI in the early phase after electroconvulsive therapy. *Neuro Res* 29:256–259.
12. Nordanskog P, Dahlstrand U, Larsson MR, Larsson EM, Knutsson L, Johanson A (2010): Increase in hippocampal volume after electroconvulsive therapy in patients with depression: A volumetric magnetic resonance imaging study. *J ECT* 26:62–67.
13. Kunigiri G, Jayakumar PN, Janakiramaiah N, Gangadhar BN (2007): MRI T(2) relaxometry of brain regions and cognitive dysfunction following electroconvulsive therapy. *Indian J Psychiatry* 49:195–199.
14. Lippman S, Manshadi M, Wehry M, Byrd R, Past W, Keller W, *et al.* (1985): 1,250 electroconvulsive treatments without evidence of brain injury. *Br J Psychiatry* 147:203–204.
15. Abdallah CG, Sanacora G, Duman RS, Krystal JH (2015): Ketamine and rapid-acting antidepressants: A window into a new neurobiology for mood disorder therapeutics. *Annu Rev Med* 66:509–523.
16. Duman RS, Aghajanian GK, Sanacora G, Krystal JH (2016): Synaptic plasticity and depression: New insights from stress and rapid-acting antidepressants. *Nat Med* 22:238–249.
17. Liu RJ, Aghajanian GK (2008): Stress blunts serotonin- and hypocretin-evoked EPSCs in prefrontal cortex: Role of corticosterone-mediated apical dendritic atrophy. *Proc Natl Acad Sci U S A* 105:359–364.
18. Qiao H, An SC, Ren W, Ma XM (2014): Progressive alterations of hippocampal CA3-CA1 synapses in an animal model of depression. *Behav Brain Res* 275:191–200.
19. Alonso R, Griebel G, Pavone G, Stemmelin J, Le Fur G, Soubrié P (2004): Blockade of CRF(1) or V(1b) receptors reverses stress-induced suppression of neurogenesis in a mouse model of depression. *Mol Psychiatry* 9:278–286., 224.
20. Boldrini M, Santiago AN, Hen R, Dwork AJ, Rosoklija GB, Tamir H, *et al.* (2013): Hippocampal granule neuron number and dentate gyrus volume in antidepressant-treated and untreated major depression. *Neuropsychopharmacology* 38:1068–1077.
21. Boldrini M, Galfalvy H, Dwork AJ, Rosoklija GB, Trencvskanovska I, Pavlovski G, *et al.* (2019): Resilience is associated with larger dentate gyrus, while suicide decedents with major depressive disorder have fewer granule neurons. *Biol Psychiatry* 85:850–862.
22. Kang HJ, Voleti B, Hajszan T, Rajkowska G, Stockmeier CA, Licznarski P, *et al.* (2012): Decreased expression of synapse-related genes and loss of synapses in major depressive disorder. *Nat Med* 18:1413–1417.
23. Schmaal L, Veltman DJ, van Erp TG, Sämann PG, Frodl T, Jahanshad N, *et al.* (2016): Subcortical brain alterations in major depressive disorder: Findings from the ENIGMA Major Depressive Disorder working group. *Mol Psychiatry* 21:806–812.
24. Schmaal L, Hibar DP, Sämann PG, Hall GB, Baune BT, Jahanshad N, *et al.* (2017): Cortical abnormalities in adults and adolescents with major depression based on brain scans from 20 cohorts worldwide in the ENIGMA Major Depressive Disorder Working Group. *Mol Psychiatry* 22:900–909.
25. Kaiser RH, Andrews-Hanna JR, Wager TD, Pizzagalli DA (2015): Large-scale network dysfunction in major depressive disorder: A meta-analysis of resting-state functional connectivity. *JAMA Psychiatry* 72:603–611.
26. van Velzen LS, Kelly S, Isaev D, Aleman A, Aftanas LI, Bauer J, *et al.* (2020): White matter disturbances in major depressive disorder: A coordinated analysis across 20 international cohorts in the ENIGMA MDD working group. *Mol Psychiatry* 25:1511–1525.
27. Mulders PC, van Eijndhoven PF, Schene AH, Beckmann CF, Tendolkar I (2015): Resting-state functional connectivity in major depressive disorder: A review. *Neurosci Biobehav Rev* 56:330–344.
28. Holmes SE, Scheinost D, Finnema SJ, Naganawa M, Davis MT, DellaGioia N, *et al.* (2019): Lower synaptic density is associated with depression severity and network alterations. *Nat Commun* 10:1529.
29. Kempermann G, Kronenberg G (2003): Depressed new neurons—Adult hippocampal neurogenesis and a cellular plasticity hypothesis of major depression. *Biol Psychiatry* 54:499–503.
30. Miller AH, Maletic V, Raison CL (2009): Inflammation and its discontents: The role of cytokines in the pathophysiology of major depression. *Biol Psychiatry* 65:732–741.
31. Belleau EL, Treadway MT, Pizzagalli DA (2019): The impact of stress and major depressive disorder on hippocampal and medial prefrontal cortex morphology. *Biol Psychiatry* 85:443–453.
32. Price RB, Duman R (2020): Neuroplasticity in cognitive and psychological mechanisms of depression: An integrative model. *Mol Psychiatry* 25:530–543.
33. Wilkinson ST, Holtzheimer PE, Gao S, Kirwin DS, Price RB (2019): Leveraging neuroplasticity to enhance adaptive learning: The potential for synergistic somatic-behavioral treatment combinations to improve clinical outcomes in depression. *Biol Psychiatry* 85:454–465.
34. Castrén E, Antila H (2017): Neuronal plasticity and neurotrophic factors in drug responses. *Mol Psychiatry* 22:1085–1095.
35. Nordanskog P, Larsson MR, Larsson EM, Johanson A (2014): Hippocampal volume in relation to clinical and cognitive outcome after electroconvulsive therapy in depression. *Acta Psychiatr Scand* 129:303–311.
36. Cano M, Lee E, Cardoner N, Martínez-Zalacain I, Pujol J, Makris N, *et al.* (2019): Brain volumetric correlates of right unilateral versus bitemporal electroconvulsive therapy for treatment-resistant depression. *J Neuropsychiatry Clin Neurosci* 31:152–158.
37. Cao B, Luo Q, Fu Y, Du L, Qiu T, Yang X, *et al.* (2018): Predicting individual responses to the electroconvulsive therapy with hippocampal subfield volumes in major depression disorder. *Sci Rep* 8:5434.
38. Dukart J, Regen F, Kherif F, Colla M, Bajbouj M, Heuser I, *et al.* (2014): Electroconvulsive therapy-induced brain plasticity determines therapeutic outcome in mood disorders. *Proc Natl Acad Sci U S A* 111:1156–1161.
39. Gryglewski G, Baldinger-Melich P, Seiger R, Godbersen GM, Michenthaler P, Klöbl M, *et al.* (2019): Structural changes in amygdala nuclei, hippocampal subfields and cortical thickness following electroconvulsive therapy in treatment-resistant depression: Longitudinal analysis. *Br J Psychiatry* 214:159–167.
40. Redlich R, Opel N, Grotegerd D, Dohm K, Zaremba D, Bürger C, *et al.* (2016): Prediction of individual response to electroconvulsive therapy via machine learning on structural magnetic resonance imaging data. *JAMA Psychiatry* 73:557–564.
41. Sartorius A, Demirakca T, Böhringer A, Clemm von Hohenberg C, Aksay SS, Bumb JM, *et al.* (2016): Electroconvulsive therapy increases temporal gray matter volume and cortical thickness. *Eur Neuropsychopharmacol* 26:506–517.
42. Sartorius A, Demirakca T, Böhringer A, Clemm von Hohenberg C, Aksay SS, Bumb JM, *et al.* (2019): Electroconvulsive therapy induced gray matter increase is not necessarily correlated with clinical data in depressed patients. *Brain Stimul* 12:335–343.
43. van Oostrom I, van Eijndhoven P, Butterbrod E, van Beek MH, Janzing J, Donders R, *et al.* (2018): Decreased cognitive functioning

- after electroconvulsive therapy is related to increased hippocampal volume: Exploring the role of brain plasticity. *J ECT* 34:117–123.
44. Bouckaert F, De Winter FL, Emsell L, Dols A, Rhebergen D, Wampers M, *et al.* (2016): Grey matter volume increase following electroconvulsive therapy in patients with late life depression: A longitudinal MRI study. *J Psychiatry Neurosci* 41:105–114.
 45. Bouckaert F, Dols A, Emsell L, De Winter FL, Vansteelandt K, Claes L, *et al.* (2016): Relationship between hippocampal volume, serum BDNF, and depression severity following electroconvulsive therapy in late-life depression. *Neuropsychopharmacology* 41:2741–2748.
 46. Xu H, Zhao T, Luo F, Zheng Y (2019): Dissociative changes in gray matter volume following electroconvulsive therapy in major depressive disorder: A longitudinal structural magnetic resonance imaging study. *Neuroradiology* 61:1297–1308.
 47. Tendolkar I, van Beek M, van Oostrom I, Mulder M, Janzing J, Voshaar RO, van Eijndhoven P (2013): Electroconvulsive therapy increases hippocampal and amygdala volume in therapy refractory depression: A longitudinal pilot study. *Psychiatry Res* 214:197–203.
 48. Van Den Bossche MJA, Emsell L, Dols A, Vansteelandt K, De Winter FL, Van den Stock J, *et al.* (2019): Hippocampal volume change following ECT is mediated by rs699947 in the promotor region of VEGF. *Transl Psychiatry* 9:191.
 49. Abbott CC, Jones T, Lemke NT, Gallegos P, McClintock SM, Mayer AR, *et al.* (2014): Hippocampal structural and functional changes associated with electroconvulsive therapy response. *Transl Psychiatry* 4:e483.
 50. Ota M, Noda T, Sato N, Okazaki M, Ishikawa M, Hattori K, *et al.* (2015): Effect of electroconvulsive therapy on gray matter volume in major depressive disorder. *J Affect Disord* 186:186–191.
 51. Yrondi A, Nemmi F, Billoux S, Giron A, Sporer M, Taib S, *et al.* (2019): Grey Matter changes in treatment-resistant depression during electroconvulsive therapy. *J Affect Disord* 258:42–49.
 52. Joshi SH, Espinoza RT, Pirmia T, Shi J, Wang Y, Ayers B, *et al.* (2016): Structural plasticity of the hippocampus and amygdala induced by electroconvulsive therapy in major depression. *Biol Psychiatry* 79:282–292.
 53. Gbysl K, Rostrup E, Raghava JM, Carlsen JF, Schmidt LS, Lindberg U, *et al.* (2019): Cortical thickness following electroconvulsive therapy in patients with depression: A longitudinal MRI study. *Acta Psychiatr Scand* 140:205–216.
 54. Belge JB, van Diermen L, Sabbe B, Parizel P, Morrens M, Coppens V, *et al.* (2020): Inflammation, hippocampal volume, and therapeutic outcome following electroconvulsive therapy in depressive patients: A pilot study. *Neuropsychobiology* 79:222–232.
 55. Cano M, Martínez-Zalacáin I, Bernabéu-Sanz Á., Contreras-Rodríguez O, Hernández-Ribas R, Via E, *et al.* (2017): Brain volumetric and metabolic correlates of electroconvulsive therapy for treatment-resistant depression: A longitudinal neuroimaging study. *Transl Psychiatry* 7:e1023.
 56. Laroy M, Bouckaert F, Vansteelandt K, Obbels J, Dols A, Emsell L, *et al.* (2019): Association between hippocampal volume change and change in memory following electroconvulsive therapy in late-life depression. *Acta Psychiatr Scand* 140:435–445.
 57. Laroy M, Weydts J, Vansteelandt K, Emsell L, Adamson C, Sienaert P, *et al.* (2019): Cortisol is not associated with pre-treatment medial temporal lobe volume or volume changes after electroconvulsive therapy in patients with late-life depression. *Psychiatry Res Neuroimaging* 291:26–33.
 58. Qiu H, Li X, Zhao W, Du L, Huang P, Fu Y, *et al.* (2016): Electroconvulsive therapy-induced brain structural and functional changes in major depressive disorders: A longitudinal study. *Med Sci Monit* 22:4577–4586.
 59. Jorgensen A, Magnusson P, Hanson LG, Kirkegaard T, Benveniste H, Lee H, *et al.* (2016): Regional brain volumes, diffusivity, and metabolite changes after electroconvulsive therapy for severe depression. *Acta Psychiatr Scand* 133:154–164.
 60. Nickl-Jockschat T, Palomero Gallagher N, Kumar V, Hoffstaedter F, Brüggemann E, Habel U, *et al.* (2016): Are morphological changes necessary to mediate the therapeutic effects of electroconvulsive therapy? *Eur Arch Psychiatry Clin Neurosci* 266:261–267.
 61. Oltedal L, Narr KL, Abbott C, Anand A, Argyelan M, Bartsch H, *et al.* (2018): Volume of the human hippocampus and clinical response following electroconvulsive therapy. *Biol Psychiatry* 84:574–581.
 62. Gbysl K, Videbech P (2018): Electroconvulsive therapy increases brain volume in major depression: A systematic review and meta-analysis. *Acta Psychiatr Scand* 138:180–195.
 63. Takamiya A, Chung JK, Liang KC, Graff-Guerrero A, Mimura M, Kishimoto T (2018): Effect of electroconvulsive therapy on hippocampal and amygdala volumes: Systematic review and meta-analysis. *Br J Psychiatry* 212:19–26.
 64. Argyelan M, Oltedal L, Deng ZD, Wade B, Bikson M, Joanlanne A, *et al.* (2019): Electric field causes volumetric changes in the human brain. *Elife* 8:e49115.
 65. Takamiya A, Plitman E, Chung JK, Chakravarty M, Graff-Guerrero A, Mimura M, Kishimoto T (2019): Acute and long-term effects of electroconvulsive therapy on human dentate gyrus. *Neuropsychopharmacology* 44:1805–1811.
 66. Gbysl K, Rostrup E, Raghava JM, Andersen C, Rosenberg R, Larsson HBW, Videbech P (2021): Volume of hippocampal subregions and clinical improvement following electroconvulsive therapy in patients with depression. *Prog Neuropsychopharmacol Biol Psychiatry* 104:110048.
 67. Nuninga JO, Mandl RCW, Boks MP, Bakker S, Somers M, Heringa SM, *et al.* (2020): Volume increase in the dentate gyrus after electroconvulsive therapy in depressed patients as measured with 7T. *Mol Psychiatry* 25:1559–1568.
 68. Pirmia T, Joshi SH, Leaver AM, Vasavada M, Njau S, Woods RP, *et al.* (2016): Electroconvulsive therapy and structural neuroplasticity in neocortical, limbic and paralimbic cortex. *Transl Psychiatry* 6:e832.
 69. van Eijndhoven P, Mulders P, Kwekkeboom L, van Oostrom I, van Beek M, Janzing J, *et al.* (2016): Bilateral ECT induces bilateral increases in regional cortical thickness. *Transl Psychiatry* 6:e874.
 70. Xu J, Wang J, Bai T, Zhang X, Li T, Hu Q, *et al.* (2019): Electroconvulsive therapy induces cortical morphological alterations in major depressive disorder revealed with surface-based morphometry analysis. *Int J Neural Syst* 29:1950005.
 71. Wade BS, Joshi SH, Njau S, Leaver AM, Vasavada M, Woods RP, *et al.* (2016): Effect of electroconvulsive therapy on striatal morphometry in major depressive disorder. *Neuropsychopharmacology* 41:2481–2491.
 72. Belge JB, Van Diermen L, Schrijvers D, Sabbe B, Constant E, de Timary P, *et al.* (2020): The basal ganglia: A central hub for the psychomotor effects of electroconvulsive therapy. *J Affect Disord* 265:239–246.
 73. Jiang R, Abbott CC, Jiang T, Du Y, Espinoza R, Narr KL, *et al.* (2018): SMRI biomarkers predict electroconvulsive treatment outcomes: Accuracy with independent data sets. *Neuropsychopharmacology* 43:1078–1087.
 74. Depping MS, Nolte HM, Hirjak D, Palm E, Hofer S, Stieltjes B, *et al.* (2017): Cerebellar volume change in response to electroconvulsive therapy in patients with major depression. *Prog Neuropsychopharmacol Biol Psychiatry* 73:31–35.
 75. Ousdal OT, Argyelan M, Narr KL, Abbott C, Wade B, Vandenbulcke M, *et al.* (2020): Brain changes induced by electroconvulsive therapy are broadly distributed. *Biol Psychiatry* 87:451–461.
 76. Jehna M, Wurm W, Pinter D, Vogel K, Holl A, Hofmann P, *et al.* (2021): Do increases in deep grey matter volumes after electroconvulsive therapy persist in patients with major depression? A longitudinal MRI-study. *J Affect Disord* 281:908–917.
 77. Leaver AM, Vasavada M, Kubicki A, Wade B, Loureiro J, Helleman G, *et al.* (2020): Hippocampal subregions and networks linked with antidepressant response to electroconvulsive therapy. *Mol Psychiatry* 85:466–476.
 78. Takamiya A, Nuninga JO, Mandl RCW, Sommer IEC, Mimura M, Kishimoto T (2019): Volume increase of the dentate gyrus induced by

- electroconvulsive therapy: Shedding light on the clinical relevance of plasticity in the hippocampus. *J ECT* 35:e57–e58.
79. Oudega ML, van Exel E, Stek ML, Wattjes MP, van der Flier WM, Comijs HC, *et al.* (2014): The structure of the geriatric depressed brain and response to electroconvulsive therapy. *Psychiatry Res* 222:1–9.
 80. Mulders PCR, Llera A, Beckmann CF, Vandenbulcke M, Stek M, Sienaert P, *et al.* (2020): Structural changes induced by electroconvulsive therapy are associated with clinical outcome. *Brain Stimul* 13:696–704.
 81. Schmitgen MM, Kubera KM, Depping MS, Nolte HM, Hirjak D, Hofer S, *et al.* (2020): Exploring cortical predictors of clinical response to electroconvulsive therapy in major depression. *Eur Arch Psychiatry Clin Neurosci* 270:253–261.
 82. Wade BS, Joshi SH, Pirmia T, Leaver AM, Woods RP, Thompson PM, *et al.* (2015): Random forest classification of depression status based on subcortical brain morphometry following electroconvulsive therapy. *Proc IEEE Int Symp Biomed Imaging* 2015:92–96.
 83. Qi S, Abbott CC, Narr KL, Jiang R, Upston J, McClintock SM, *et al.* (2020): Electroconvulsive therapy treatment responsive multimodal brain networks. *Hum Brain Mapp* 41:1775–1785.
 84. Le Bihan D, Johansen-Berg H (2012): Diffusion MRI at 25: Exploring brain tissue structure and function. *Neuroimage* 61:324–341.
 85. Le Bihan D (2003): Looking into the functional architecture of the brain with diffusion MRI. *Nat Rev Neurosci* 4:469–480.
 86. Jbabdi S, Sotiropoulos SN, Haber SN, Van Essen DC, Behrens TE (2015): Measuring macroscopic brain connections in vivo. *Nat Neurosci* 18:1546–1555.
 87. Lyden H, Espinoza RT, Pirmia T, Clark K, Joshi SH, Leaver AM, *et al.* (2014): Electroconvulsive therapy mediates neuroplasticity of white matter microstructure in major depression. *Transl Psychiatry* 4:e380.
 88. Nobuhara K, Okugawa G, Minami T, Takase K, Yoshida T, Yagyu T, *et al.* (2004): Effects of electroconvulsive therapy on frontal white matter in late-life depression: A diffusion tensor imaging study. *Neuropsychobiology* 50:48–53.
 89. Gryglewski G, Seiger R, Baldinger-Melich P, Unterholzner J, Spurny B, Vanicek T, *et al.* (2020): Changes in white matter microstructure after electroconvulsive therapy for treatment-resistant depression. *Int J Neuropsychopharmacol* 23:20–25.
 90. Yrondi A, Nemmi F, Billoux S, Giron A, Sporer M, Taib S, *et al.* (2019): Significant decrease in hippocampus and amygdala mean diffusivity in treatment-resistant depression patients who respond to electroconvulsive therapy. *Front Psychiatry* 10:694.
 91. Nuninga JO, Mandl RCW, Froeling M, Siero JCW, Somers M, Boks MP, *et al.* (2020): Vasogenic edema versus neuroplasticity as neural correlates of hippocampal volume increase following electroconvulsive therapy. *Brain Stimul* 13:1080–1086.
 92. Kubicki A, Leaver AM, Vasavada M, Njau S, Wade B, Joshi SH, *et al.* (2019): Variations in hippocampal white matter diffusivity differentiate response to electroconvulsive therapy in major depression. *Biol Psychiatry Cogn Neurosci Neuroimaging* 4:300–309.
 93. Obergrösser T, Ende G, Braus DF, Henn FA (2003): Long-term follow-up of magnetic resonance-detectable choline signal changes in the hippocampus of patients treated with electroconvulsive therapy. *J Clin Psychiatry* 64:775–780.
 94. Ende G, Braus DF, Walter S, Weber-Fahr W, Henn FA (2000): The hippocampus in patients treated with electroconvulsive therapy: A proton magnetic resonance spectroscopic imaging study. *Arch Gen Psychiatry* 57:937–943.
 95. Merkl A, Schubert F, Quante A, Luborzewski A, Brakemeier EL, Grimm S, *et al.* (2011): Abnormal cingulate and prefrontal cortical neurochemistry in major depression after electroconvulsive therapy. *Biol Psychiatry* 69:772–779.
 96. Michael N, Erfurth A, Ohrmann P, Arolt V, Heindel W, Pfeleiderer B (2003): Metabolic changes within the left dorsolateral prefrontal cortex occurring with electroconvulsive therapy in patients with treatment resistant unipolar depression. *Psychol Med* 33:1277–1284.
 97. Michael N, Erfurth A, Ohrmann P, Arolt V, Heindel W, Pfeleiderer B (2003): Neurotrophic effects of electroconvulsive therapy: A proton magnetic resonance study of the left amygdalar region in patients with treatment-resistant depression. *Neuropsychopharmacology* 28:720–725.
 98. Tosun Ş., Tosun M, Akansel G, Gökbakan AM, Ünver H, Tural Ü. (2020): Proton magnetic resonance spectroscopic analysis of changes in brain metabolites following electroconvulsive therapy in patients with major depressive disorder. *Int J Psychiatry Clin Pract* 24:96–101.
 99. Knudsen MK, Near J, Blicher AB, Videbech P, Blicher JU (2019): Magnetic resonance (MR) spectroscopic measurement of γ -aminobutyric acid (GABA) in major depression before and after electroconvulsive therapy. *Acta Neuropsychiatr* 31:17–26.
 100. Njau S, Joshi SH, Espinoza R, Leaver AM, Vasavada M, Marquina A, *et al.* (2017): Neurochemical correlates of rapid treatment response to electroconvulsive therapy in patients with major depression. *J Psychiatry Neurosci* 42:6–16.
 101. Zhang J, Narr KL, Woods RP, Phillips OR, Alger JR, Espinoza RT (2013): Glutamate normalization with ECT treatment response in major depression. *Mol Psychiatry* 18:268–270.
 102. Erchinger VJ, Ersland L, Aukland SM, Abbott CC, Oltedal L (2021): Magnetic resonance spectroscopy in depressed subjects treated with electroconvulsive therapy—A systematic review of literature. *Front Psychiatry* 12:608857.
 103. Coffey CE, Lucke J, Weiner RD, Krystal AD, Aque M (1995): Seizure threshold in electroconvulsive therapy (ECT) II. The anticonvulsant effect of ECT. *Biol Psychiatry* 37:777–788.
 104. Krystal AD, Coffey CE, Weiner RD, Holsinger T (1998): Changes in seizure threshold over the course of electroconvulsive therapy affect therapeutic response and are detected by ictal EEG ratings. *J Neuropsychiatry Clin Neurosci* 10:178–186.
 105. Sackeim HA (1999): The anticonvulsant hypothesis of the mechanisms of action of ECT: Current status. *J ECT* 15:5–26.
 106. Sanacora G, Mason GF, Rothman DL, Hyder F, Ciarcia JJ, Ostroff RB, *et al.* (2003): Increased cortical GABA concentrations in depressed patients receiving ECT. *Am J Psychiatry* 160:577–579.
 107. Erchinger VJ, Miller J, Jones T, Kessler U, Bustillo J, Haavik J, *et al.* (2020): Anterior cingulate gamma-aminobutyric acid concentrations and electroconvulsive therapy. *Brain Behav* 10:e01833.
 108. Pfeleiderer B, Michael N, Erfurth A, Ohrmann P, Hohmann U, Wolgast M, *et al.* (2003): Effective electroconvulsive therapy reverses glutamate/glutamine deficit in the left anterior cingulum of unipolar depressed patients. *Psychiatry Res* 122:185–192.
 109. Madsen TM, Treschow A, Bengzon J, Bolwig TG, Lindvall O, Tingström A (2000): Increased neurogenesis in a model of electroconvulsive therapy. *Biol Psychiatry* 47:1043–1049.
 110. Santarelli L, Saxe M, Gross C, Surget A, Battaglia F, Dulawa S, *et al.* (2003): Requirement of hippocampal neurogenesis for the behavioral effects of antidepressants. *Science* 301:805–809.
 111. Olesen MV, Wörtwein G, Folke J, Pakkenberg B (2017): Electroconvulsive stimulation results in long-term survival of newly generated hippocampal neurons in rats. *Hippocampus* 27:52–60.
 112. Malberg JE, Eisch AJ, Nestler EJ, Duman RS (2000): Chronic antidepressant treatment increases neurogenesis in adult rat hippocampus. *J Neurosci* 20:9104–9110.
 113. Sierra A, Encinas JM, Maletic-Savatic M (2011): Adult human neurogenesis: From microscopy to magnetic resonance imaging. *Front Neurosci* 5:47.
 114. Kornack DR, Rakic P (1999): Continuation of neurogenesis in the hippocampus of the adult macaque monkey. *Proc Natl Acad Sci U S A* 96:5768–5773.
 115. Willard SL, Riddle DR, Forbes ME, Shively CA (2013): Cell number and neurofilament alterations in subregions of the anterior hippocampus in a female monkey model of depression. *Biol Psychiatry* 74:890–897.
 116. Kohler SJ, Williams NI, Stanton GB, Cameron JL, Greenough WT (2011): Maturation time of new granule cells in the dentate gyrus of adult macaque monkeys exceeds six months. *Proc Natl Acad Sci U S A* 108:10326–10331.

117. Hellsten J, West MJ, Arvidsson A, Ekstrand J, Jansson L, Wennström M, Tingström A (2005): Electroconvulsive seizures induce angiogenesis in adult rat hippocampus. *Biol Psychiatry* 58:871–878.
118. Wennström M, Hellsten J, Tingström A (2004): Electroconvulsive seizures induce proliferation of NG2-expressing glial cells in adult rat amygdala. *Biol Psychiatry* 55:464–471.
119. Vaidya VA, Siuciak JA, Du F, Duman RS (1999): Hippocampal mossy fiber sprouting induced by chronic electroconvulsive seizures. *Neuroscience* 89:157–166.
120. Keifer OP, Hurt RC, Gutman DA, Keilholz SD, Gourley SL, Ressler KJ (2015): Voxel-based morphometry predicts shifts in dendritic spine density and morphology with auditory fear conditioning. *Nat Commun* 6:7582.
121. Kassem MS, Lagopoulos J, Stait-Gardner T, Price WS, Chohan TW, Arnold JC, *et al.* (2013): Stress-induced grey matter loss determined by MRI is primarily due to loss of dendrites and their synapses. *Mol Neurobiol* 47:645–661.
122. Smitha JS, Roopa R, Khaleel N, Kutty BM, Andrade C (2014): Images in electroconvulsive therapy: Electroconvulsive shocks dose-dependently increase dendritic arborization in the CA1 region of the rat hippocampus. *J ECT* 30:191–192.
123. Lerch JP, Yiu AP, Martinez-Canabal A, Pekar T, Bohbot VD, Frankland PW, *et al.* (2011): Maze training in mice induces MRI-detectable brain shape changes specific to the type of learning. *Neuroimage* 54:2086–2095.
124. Golub Y, Kaltwasser SF, Mauch CP, Herrmann L, Schmidt U, Holsboer F, *et al.* (2011): Reduced hippocampus volume in the mouse model of Posttraumatic Stress Disorder. *J Psychiatr Res* 45:650–659.
125. Franklin TR, Wang Z, Shin J, Jagannathan K, Suh JJ, Detre JA, *et al.* (2013): A VBM study demonstrating ‘apparent’ effects of a single dose of medication on T1-weighted MRIs. *Brain Struct Funct* 218:97–104.
126. Leaver AM, Vasavada M, Joshi SH, Wade B, Woods RP, Espinoza R, Narr KL (2019): Mechanisms of antidepressant response to electroconvulsive therapy studied with perfusion magnetic resonance imaging. *Biol Psychiatry* 85:466–476.
127. Andrade C, Bolwig TG (2014): Electroconvulsive therapy, hypertensive surge, blood-brain barrier breach, and amnesia: Exploring the evidence for a connection. *J ECT* 30:160–164.
128. Sackeim HA (2020): The impact of electroconvulsive therapy on brain grey matter volume: What does it mean? *Brain Stimul* 13:1226–1231.
129. Hesse GW, Teyler TJ (1976): Reversible loss of hippocampal long term potentiation following electroconvulsive seizures. *Nature* 264:562–564.
130. Stewart C, Jeffery K, Reid I (1994): LTP-like synaptic efficacy changes following electroconvulsive stimulation. *NeuroReport* 5:1041–1044.
131. Stagg C, Rothman DL (2014): *Magnetic Resonance Spectroscopy: Tools for Neuroscience Research and Emerging Clinical Applications*. London: Academic Press.
132. Perrin JS, Merz S, Bennett DM, Currie J, Steele DJ, Reid IC, Schwarzbauer C (2012): Electroconvulsive therapy reduces frontal cortical connectivity in severe depressive disorder. *Proc Natl Acad Sci U S A* 109:5464–5468.
133. Argyelan M, Lencz T, Kaliora S, Sarpal DK, Weissman N, Kingsley PB, *et al.* (2016): Subgenual cingulate cortical activity predicts the efficacy of electroconvulsive therapy. *Transl Psychiatry* 6:e789.
134. Bai T, Wei Q, Xie W, Wang A, Wang J, Ji GJ, *et al.* (2019): Hippocampal-subregion functional alterations associated with antidepressant effects and cognitive impairments of electroconvulsive therapy. *Psychol Med* 49:1357–1364.
135. Magne Bjølseth T, Engedal K, Šaltytė Benth J, Bergsholm P, Strømnes Dybedal G, Lødøen Gaarden T, Tanum L (2016): Speed of recovery from disorientation may predict the treatment outcome of electroconvulsive therapy (ECT) in elderly patients with major depression. *J Affect Disord* 190:178–186.
136. Sackeim HA, Prudic J, Devanand DP, Nobler MS, Lisanby SH, Peyser S, *et al.* (2000): A prospective, randomized, double-blind comparison of bilateral and right unilateral electroconvulsive therapy at different stimulus intensities. *Arch Gen Psychiatry* 57:425–434.
137. Abbott CC, Quinn D, Miller J, Ye E, Iqbal S, Lloyd M, *et al.* (2021): Electroconvulsive therapy pulse amplitude and clinical outcomes. *Am J Geriatr Psychiatry* 29:166–178.
138. Ousdal OT, Kaufmann T, Kolskår K, Vik A, Wehling E, Lundervold AJ, *et al.* (2020): Longitudinal stability of the brain functional connectome is associated with episodic memory performance in aging. *Hum Brain Mapp* 41:697–709.
139. Finn ES, Shen X, Scheinost D, Rosenberg MD, Huang J, Chun MM, *et al.* (2015): Functional connectome fingerprinting: Identifying individuals using patterns of brain connectivity. *Nat Neurosci* 18:1664–1671.
140. Kaufmann T, Alnæs D, Doan NT, Brandt CL, Andreassen OA, Westlye LT (2017): Delayed stabilization and individualization in connectome development are related to psychiatric disorders. *Nat Neurosci* 20:513–515.
141. Zhang H, Schneider T, Wheeler-Kingshott CA, Alexander DC (2012): NODDI: Practical in vivo neurite orientation dispersion and density imaging of the human brain. *Neuroimage* 61:1000–1016.
142. White NS, Leergaard TB, D’Arceuil H, Bjaalie JG, Dale AM (2013): Probing tissue microstructure with restriction spectrum imaging: Histological and theoretical validation. *Hum Brain Mapp* 34:327–346.
143. Kaden E, Kruggel F, Alexander DC (2016): Quantitative mapping of the per-axon diffusion coefficients in brain white matter. *Magn Reson Med* 75:1752–1763.
144. Fink M (2014): The seizure, not electricity, is essential in convulsive therapy: The flurothyl experience. *J ECT* 30:91–93.
145. Luber B, Nobler MS, Moeller JR, Katzman GP, Prudic J, Devanand DP, *et al.* (2000): Quantitative EEG during seizures induced by electroconvulsive therapy: Relations to treatment modality and clinical features. II. Topographic analyses. *J ECT* 16:229–243.